

Anhidrotic ectodermal dysplasia in infancy – Case of misconduct of hyperthermia

Milind R. Kulkarni^{1,*}, A. V. Badakali², B. C. Yelamali³, Vinay Kumar⁴

¹Resident, ^{2,3}Professor, ⁴Assistant Professor, Dept. of Paediatrics, S. Nijalingappa Medical College & H.S.K. Hospital & Research Centre Navanagar, Karnataka, India

***Corresponding Author:**

Email: milindrkcimr@gmail.com

Abstract

Ectodermal dysplasias are a group of hereditary disorders with improper development of embryonal ectodermal layer. The diagnosis of these disorders is challenging during infancy and it must be considered while investigating infants or neonates with fever without focus and dehydration. In the infants, clinical signs of this condition are subtle and non-specific. The classical signs of the disease become more visible after a few months of life. Paediatricians should have high index of suspicion of anhidrotic ectodermal dysplasia in infants or neonates presenting with fever without focus and dehydration especially in summer season. We report this rare clinical entity and supplicate to consider the diagnosis of anhidrotic ectodermal dysplasia when investigating pyrexia of unknown origin (PUO) or hyperthermia in infants during summer especially in areas of semi arid climate and dry weather.

Keywords: External dysplasia, Anhidrotic, Pyrexia of unknown origin.

Introduction

Ectodermal dysplasias are assorted cluster of hereditary diseases characterized by various abnormalities in tissues and organs of ectodermal origin.^{1,2} The two major types of this disorder are anhidrotic and hypohidrotic forms.¹

The first description of this disorder involving skin, hair, and teeth was given by Thurman in the year 1848.³⁻⁵ Anhidrotic ectodermal dysplasia is an X-linked recessive disorder. This condition constitutes the triad of total absence of sweat glands, hypotrichosis, and hypodontia.³ This disorder predominantly affects males which constitute 90% of the cases.

Case Report

A 2 month old male infant presented with recurrent history of intermittent fever since the birth. Fever had diurnal variation with febrile episodes more during day. On physical examination, baby had dry skin and mucous membranes and was febrile (100.4 degree Fahrenheit). In order to investigate the origin of the fever we carried out chest X-ray, blood analysis, and urinalysis. All these investigations turned out to be normal. We started empiric therapy with cefotaxim and antipyretic for fever. Baby's peak temperatures persisted throughout the day and had no febrile episodes during night hours. Subsequently, various serological investigation for "fever with no focus" were carried out which were non productive.

We observed the baby fever pattern to be raised during day with peak temperature of 103 degree Fahrenheit while during night hours had peak temperature of 99.8 degree Fahrenheit with child always been irritable though there was no refusal to feeds. On enquiry patient mother told that the baby had also no sweating and it was also observed that baby had sparse hair throughout body. Thus, anhidrotic ectodermal

dysplasia was suspected. Sample for skin biopsy was taken from the back of the infant. Histo-pathological specimen confirmed absence of sweat glands with hypoplasia of follicular structures (Fig. 1). The mother was explained about the disease and use of cotton clothes, avoidance of exposure of the baby to hot weather and application of emollient for dry skin was advised.

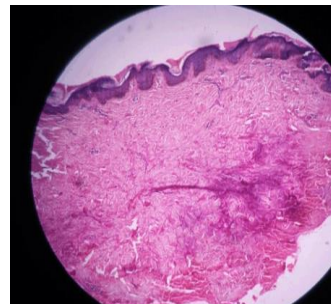


Fig. 1: Histo-pathologic characteristics of absence of eccrine and sebaceous glands

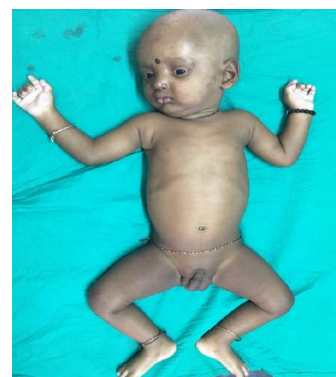

Fig. 2: Typical facies of the patient with anhidrotic ectodermal dysplasia

Discussion

Anhidrotic ectodermal dysplasia is a heterogeneous genetic disorder with various forms of inheritance like autosomal dominant, autosomal recessive^{4,6} and X-linked recessive.^{7,8} Male patients are more seriously affected by the disease, with significant morbidity and mortality.⁸ Heterozygote women can be affected differently,⁸⁻¹⁰ ranging from being asymptomatic carriers to presenting clinical manifestation identical to males.⁶

The clinical features include absent or reduced sweat, hypotrichosis, hypodontia, and typical facies³ as described in Fig. 2. The hypotrichosis is generalized with hair being thin, sparse, dry, and with reduced pigmentation but the eyelashes being normal.³ Also they have dry skin with signs of early ageing. Dental abnormalities include anodontia or hypodontia with the incisor and/or canine teeth being conoid, and pointed.³⁻⁵ Infants have persistent hyperthermia especially in the summer due to absence of sweating as there are no sweat glands.

The diagnosis of this condition is clinically difficult as physical findings are not prominent. In that case, history of anhidrosis become very relevant and diagnosis can be confirmed with histo-pathological examination of the skin. Recently, it is also possible to carry out prenatal genetic testing.^{3,7}

Treatment basically focuses on keeping the infants in ambient temperature and to avoid dry hot weather.

We conclude that despite being rare, it is necessary to consider this disorder in diagnosis of fever of unknown origin and dehydration. Thus, it would be possible for early diagnosis of the disease avoiding unnecessary use of resources in form of investigations and medications in cases of fever of unknown origin in newborns and infants.

Funding: No funding sources.

Conflict of interest: None declared.

References

1. Paller AS. Hereditary disease of skin, hair, nails, and skin structure. In: Maldonado L, Parish B, eds. Paediatric dermatology. Philadelphia: Grune & Stratton; 1989:85.
2. Argenziano G, Monsurrò MR, Paziienza R, Delfino M. A case of probable autosomal recessive ectodermal dysplasia with corkscrew hairs and mental retardation in a family with tuberous sclerosis. *JAAD* 1998;38:344-48.
3. Rook A, Wilkinson DS, Ebling FJG. Textbook of dermatology. In: Harper JI, ed. 6th ed. Great Britain: By Champion; 1998:391-95.
4. Kirtikant CS, Dipak DU. Unusual cutaneous manifestations of anhidrotic ectodermal dysplasia. *J Dermatol* 1990;17: 380-84.
5. Hizli J, Özdemir S, Bakaloglu A. Anhidrotic ectodermal dysplasia (Christ-Siemens-Touraine Syndrome) presenting as a fever of unknown origin in an infant. *Int J Dermatol* 1988;37:128-44.
6. Munoz F, Lestringant G, Sybert V, Frydman M, Alswaini A, Frossard PM, et al. Definitive evidence for an autosomal recessive form of hypohidrotic dysplasia clinically indistinguishable from the more common X-linked disorder. *Am J Hum Genet* 1997;61:94-100.
7. Fitzpatrick TB, Eisen AZ, Wolff C, Austen KF, Goldsmith LA, Katz EI. Dermatology in general medicine. In: Goldsmith LA, ed. 5th ed. USA: Mc Graw-Hill 1999:805-6.
8. Norval EJG, Van Wyk CW, Basson NJ, Coldrey J. Hypohidrotic ectodermal dysplasia: a genealogic, stereomicroscope, and scanning electron microscope study. *Pediatr Dermatol* 1988;3:159-66.
9. Micali G, Cook B, Blekys I, Solomon LM. Structural hair abnormalities in ectodermal dysplasia. *Pediatr Dermatol* 1990;7:27-32.
10. Zonana J. Hypohidrotic ectodermal dysplasia: molecular genetics research and its clinical applications. *Semin Dermatol* 1993;12:241-6.

How to cite the article: Kulkarni M, Badakali A., Yelamali B., Kumar V. Anhidrotic ectodermal dysplasia in infancy – Case of misconduct of hyperthermia. *IP Int J Med Paediatr Oncol* 2018;4(3):129-130.