

Acute myeloid leukemia/ transient abnormal myelopoiesis masquerading as sepsis in a neonate with down syndrome

Naved Akter¹, Veenu Agarwal^{2*}, Prachi Kumar³

¹Resident Doctor, ²Professor, Dept. of Pediatrics, ³Assistant Professor, Dept. of Pathology, Santosh Medical College, Ghaziabad

***Corresponding Author:**

Email: veenu2908@gmail.com

Abstract

A term 7 day old girl with phenotype of Down syndrome presented with irritability, poor feeding and respiratory distress for one day. She had echymotic patches on trunk and arm, moderate hepato-splenomegaly, swollen cyanosed cold right forearm. Neonatal sepsis was suspected but sepsis screen was negative. Peripheral blood smear revealed marked leucocytosis with 70% myeloblast cells, thrombocytopenia and normal erythrocyte count. Bone marrow had 48% myeloblasts. Differential diagnosis of transient abnormal myelopoiesis (with life threatening symptoms) and congenital leukemia were kept. We chose to report this case as it highlights the association between commonest chromosomal anomaly- Down syndrome and various hematological anomalies.

Keywords: Down Syndrome, Congenital Leukemia, Transient abnormal myelopoiesis.

Introduction

Down syndrome (DS) is the commonest chromosomal anomaly with prevalence of around 1/600 -1/800 live births. Children with DS exhibit unique predisposition for various hemato-oncological abnormalities and are at 500 fold increased risk of developing acute megakaryoblastic leukemia (AMKL), a subtype of acute myeloid leukemia (FAB classification M7) than in the general pediatric population.^(1,2) Approximately 10% of newborn infants with DS develop transient leukemia also referred to as transient abnormal myelopoiesis (TAM). Spontaneous resolution of TAM in most (70-80%) cases delineates it from otherwise clinically indistinguishable AMKL.^(3,4,5) In both these conditions, immature megakaryoblasts accumulate in liver, bone marrow and peripheral blood. Majority of such infants may be clinically well at presentation with an incidental finding of circulating blasts in the blood.

Here we are presenting a case of clinical DS in whom clinical possibility of TAM with many life threatening features(LTS) and congenital leukemia were kept.

Case Report

7 day old baby girl brought with complaints of poor feeding, grunting, excessive crying and irritability of 1 day duration. She was born to 23 yr old third gravida mother by normal vaginal delivery at term gestation with birth weight of 2.5 kg. Antenatal period was uneventful. Mother's blood group was B positive. There were no complaints prior to present illness. At admission she was sick, had peripheral cyanosis. Pointers of down syndrome present were brachycephaly, epicanthal folds, mongoloid slant of eyes, low set ears, short webbed neck, nuchal fold of skin at occiput, pad of fat at neck, widely spaced nipples, clinodactyly and saddle gap in toes. She had tachypnea, chest wall retractions and coarse crepitations. She also had hepatomegaly (5 cm),

splenomegaly (3.5 cm) and echymotic patches on trunk with feature of veno-occlusive right upper limb (hand to elbow) swelling which was cyanosed and cold.

Provisional diagnosis of neonatal septicemia with broncho-pneumonia with seizures and (clinical suspicion of) Down syndrome was kept. Investigations revealed Hb 14.9gm%, RBC count was normal (4.6million/cmm), thrombocytopenia (30,000/cumm) and marked leukocytosis (90,000/cu mm). Peripheral blood film showed 70% blasts, 3% promyelocytes, 3% metamyelocytes, 12% neutrophils, 9% lymphocytes, 1% eosinophils and 2% monocytes (Fig. 2). There were no features of hemolysis. C - reactive protein was negative. CSF examination was normal. Portable chest X-ray showed diffuse lung infiltrates with no evidence of cardiomegaly. Serum LDH was elevated 1520U/L(Normal value 450U/L). Bone Marrow done post mortem revealed 48% blasts.

Neonate was managed conservatively and at 2 hours post hospitalization she developed GI bleed, worsening respiratory distress and pulmonary hemorrhage and expired. Bone marrow aspiration was done postmortem.

Special stains and Immuno-phenotyping (to identify the type of leukemia) and karyo-typing (to confirm the diagnosis of Down syndrome) could not be done due to scarcity of time. Parents refused for autopsy.

Discussion

Leukocytosis is a commonly encountered finding in neonates which could be physiologic leukocytosis in which TLC ranges from 9000 to 30000/cmm and appears to be due to a surge in cytosine secretion (GCSF and GMCSF) in the immediate postpartum period.⁽³⁾

Infections are the other important cause of leukocytosis and may manifest as leukemoid reaction which has moderate to extreme degree of leukocytosis, somewhat similar to leukemia but it has orderly

morphological shift of WBC to left along with normal bone marrow and high leucocyte alkaline phosphatase.

As sepsis screening was negative in present case but she had remarkable hepato-splenomegaly, peripheral bleeding and veno-occlusive involvement of right upper limb, possibility of TAM with LTS /AMKL-DS/CL were kept.

Down syndrome (DS) is the most common chromosomal abnormality and is characterized by easily recognisable physical features, besides various cardiac, gastrointestinal, skeletal and endocrine defects. They are also at increased risk of developing distinctive clonal myeloid disorders, including transient abnormal myelopoiesis (TAM), myeloid leukaemia of DS (ML-DS) and acute lymphoblastic leukaemia(ALL-DS). Among DS newborns, TAM is observed in around 10%-20% babies⁽¹⁾ while prevalence of ML-DS and ALL-DS are increased by 150- and ~30-fold, than in general paediatric population.⁽²⁾ The commonest subtype of ML-DS (is Acute megakaryoblastic leukemia (FAB- M7).

Most infants with TAM infants are clinically well at presentation and diagnosis is due to an incidental finding of circulating blasts in the blood. Broad eligibility criteria used by Gamis et al⁽⁵⁾ were <3 months of age at presentation with any non-erythroid blasts in the peripheral blood coupled with any of the 5 following criteria: verification of blasts with a second sample, >5% nonerythroid BM blasts, hepatomegaly or splenomegaly, lymphadenopathy, or cardiac or pleural effusions. In some cases the disease is severe and potentially lethal. Life-threatening symptoms (LTS) defined by Gamis et al were one or more of the following: signs of hyperviscosity, blast count >100,000/ μ L, hepatosplenomegaly causing respiratory compromise, heart failure (ejection fraction <47% or shortening fraction < 27%) not directly the result of a congenital heart defect, hydrops fetalis, renal or hepatic dysfunction, or disseminated intravascular coagulation (DIC) with bleeding. The characteristic features of TAM are numerous circulating blast cells, exceeding the number of blast cells in the bone marrow.

AMKL and TMA in DS show strikingly similar morphologic features. The main difference in the clinical presentation of these disorders is the age of onset. AMKL virtually always develops before the age of 5 years after a period of apparent remission (1–4 years). Bone marrow trephine studies, flow cytometry, immunotyping and cytoanalytic studies may be needed to detect certain mutations in the blast cells which although remain ‘silent’ clinically and haematologically but predisposes these babies to higher risk of progression of TAM to ML-DS. Usually ML-DS is treatment-responsive⁽⁶⁾ but the associated mortality rate in ML-DS may be up to 20%.

Congenital leukemia especially ALL-MS are also commoner in children with DS and constitute around 0.8% of all pediatric leukemia cases. CL has worst

prognosis among all haematological anomalies associated with DS.

Differentiation between congenital leukaemia and transient myeloproliferative disorder is difficult as both may have same haematological symptoms, the only difference being non-hematopoietic tissue infiltration (skin and central nervous system) which is commoner in congenital leukaemia.^(5,6) While the presence of trisomy and other abnormalities of chromosome 21 in baby goes in favour of diagnosis of transient myeloproliferative disorder. So as stated by Kshirsagar et al⁽³⁾ peripheral blood smear examination in DS children during neonatal period can be of help in early detection of these haematological conditions with varied prognosis.

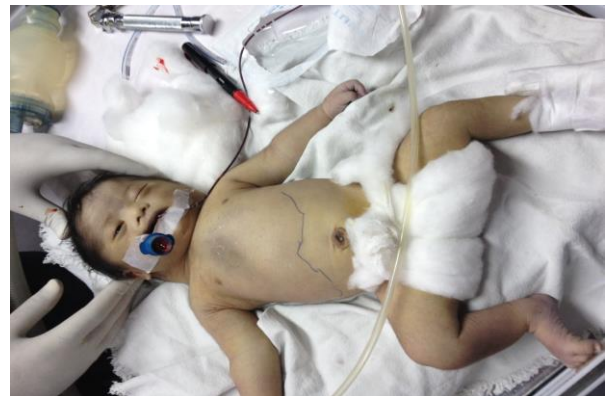

Fig. 1: Clinical photograph of neonate showing down facies, echymotic patch on trunk, swollen and cyanosed right fore-arm, enlarged liver & Spleen

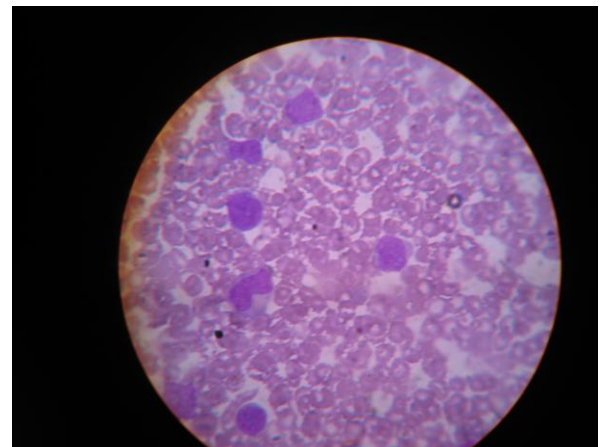


Fig. 2: Peripheral smear showing blast cells and neutrophils (giemsa stain 100 x power)

References

1. Lum SH, Choong SS, Krishnan S, Mohamed Z, Ariffin H. GATA1 mutations in a cohort of Malaysian children with Down syndrome-associated myeloid disorder. *Singapore Med J.* 2016 Jun;57(6):320-4.
2. Bhatnagar N, Nizery L, Tunstall O, Vyas P, Roberts I. Transient Abnormal Myelopoiesis and AML in Down Syndrome: an Update . *Curr Hematol Malig Rep* (2016) 11:333–341.

3. Kshirsagar VY, Ahmed M, Colaco SM, Ahmed M. Transient myeloproliferative disorder in Down's syndrome. *Indian J Pathol Microbiol* 2012;55:426-7.
4. David Webb, Irene Roberts, Paresh Vyas. Haematology of Down syndrome. *Arch Dis Child Fetal Neonatal Ed* 2007;92:F503–F507.
5. Gamis AS, Alonzo TA, Gerbing RB, Hilden J M, Sorrell AD, Sharma M, et al. Natural history of transient myeloproliferative disorder clinically diagnosed in Down syndrome neonates: a report from the Children's Oncology Group Study A2971. *Blood*. 2011 Dec 22; 118(26): 6752–6759. Prepublished online 2011 Aug 17. doi: 10.1182/blood-2011-04-350017.
6. Gurbuxani S, Vyas P, Crispino JD. Recent insights into the mechanisms of myeloid leukemogenesis in Down syndrome. *Blood* 2004;103:399-406.