

## Ring enhancing lesions on neuroimaging of childhood symptomatic epilepsy- A clinico-pathological study

Pravakar Mishra<sup>1,\*</sup>, Deepak Ranjan B.<sup>2</sup>, N.K Pattnaik<sup>3</sup>

<sup>1</sup>Associate Professor, <sup>2</sup>Junior Resident, Dept. of Pediatrics, MKCG Medical College, Berhampur, Odisha, <sup>3</sup>Consultant Cardiothoracic Surgeon, Dept. of CTVS, Apollo Hospital, Bhubaneswar, Odisha

**\*Corresponding Author:**

Email: drpravakar@yahoo.co.in, drpmishra61@gmail.com

### Abstract

Seizures are the most common pediatric neurologic disorders with 4% to 10% of children suffering at least one seizure in the first 16 years of life. More than half of CT scans are found to be abnormal in childhood symptomatic seizures. Finding out a cause and early treatment can be not only life-saving but can increase the IQ and long term survival of a child. Ring enhancing lesion is a neuroimaging finding detected in selected cases of seizures in children. It is an abnormal radiologic sign that appears as hypodense or isodense disc or target lesion with perifocal vasogenic edema. Worldwide, Neurocysticercosis prevails as the top most cause while Tuberculoma is the commonest cause in developing countries. This was a hospital based prospective study aimed to find out the clinicopathological features of seizures in 5-14 years age group showing ring enhancing lesion on neuroimaging. Out of 42 cases, majority of lesions found were tuberculoma (38%) followed by neurocysticercosis (33%) and brain abscess (20%). Nearly half of all lesions were detected in parietal lobe. Among tuberculoma cases, 13 lesions (81.2%) were found to be solitary and one was multiple (6.3%). But, out of all neurocysticercosis cases 7 (50%) were multiple and 5 (35.7%) were solitary lesions. Out of 42 cases, 24 (57.1%) got cured, 12 (28.6%) died and 6 children (14.3%) survived with sequelae after successful therapy. Distinguishing non-neoplastic causes from neoplastic ones is important because a misdiagnosis can lead to unwarranted neurosurgery and exposure to toxic chemotherapy and harmful brain irradiation.

**Keywords:** Seizure, Ring enhancing lesion, Neuroimaging, Tuberculoma, Neurocysticercosis.

### Introduction

Seizure is a very common problem encountered in Pediatric emergency. Worldwide 65 million people have seizure at least once in lifetime among which 30% occur in children. Seizures in children can be divided as idiopathic and symptomatic. The first group shows no abnormality in radio-imaging and for the second, neuroimaging (CT/MRI) is must to give a clue to diagnosis. It is widely agreed that neuroimaging is not required for all children with seizures. Selective indications being partial seizure, unprovoked seizure, late new onset seizure, presence of trauma etc.<sup>(1)</sup> Ring Enhancing Lesion is an abnormal radiologic sign on neuroimaging appearing as hypo-dense or iso-dense disc or target lesion with peri-focal edema. The commonest cause of ring enhancing lesion all over the globe is neurocysticercosis, but tuberculoma predominates in developing countries like India. HIV/AIDS, toxoplasmosis, granuloma, cryptococcosis, brain abscess, tumor, resolving hematoma and infarcts can also be seen as ring enhancing lesions. Clinical presentation in a child with seizure and radiologic ring enhancing lesion may include monoparesis, hemiparesis, severe headache, ataxia, raised intracranial tension and cranial nerve palsy. Even after thorough clinical examination, the cause of many childhood seizures remains unknown.

### Materials & Methods

This study was aimed to find out the incidence, age and sex distribution of seizures in 5-14 years age group

showing ring enhancing lesion on neuroimaging. It was planned to evaluate the clinical profile, etiological factors responsible and to observe the response to treatment. This was a hospital based prospective study evaluating all cases of seizures (any episode, any type and with any time duration) between 5-14 years admitted to Pediatric ward of MKCG Medical College & Hospital over a period of 2 years from October-2014 to September-2016. Children below 5 years and above 15 years, those having definite CNS infections, with head injury, cerebral palsy and those not showing ring enhancing brain lesion were excluded from study. Detailed history, thorough clinical examinations and investigations along the line of probable etiology were carried out. The well-known causes of seizure diagnosed clinically (head trauma, cerebral palsy) or by investigation (blood sugar, Serum electrolytes, MP-ICT, CSF study) were ruled out before ordering neuroimaging.

### Results

42 children presenting with seizure within 5-14 years with definite ring enhancing lesions were studied in detail.

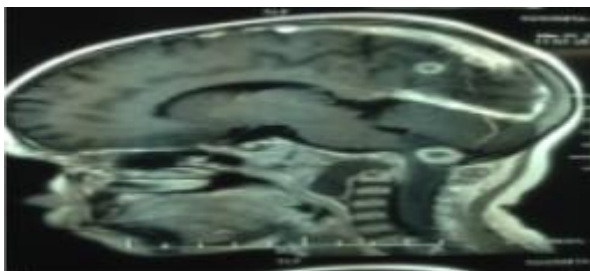

Fig. 1: Ring enhancing lesion on CT scan of brain

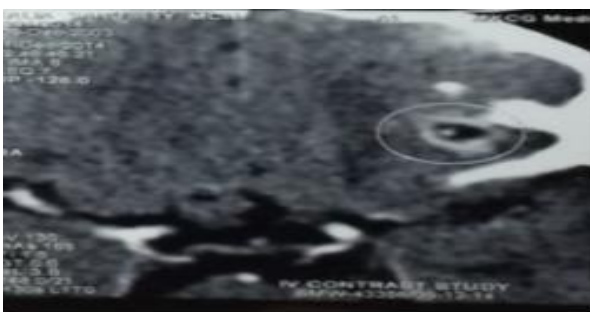

Fig. 2: Scolex with head of Neurocysticercosis seen on CT scan of brain

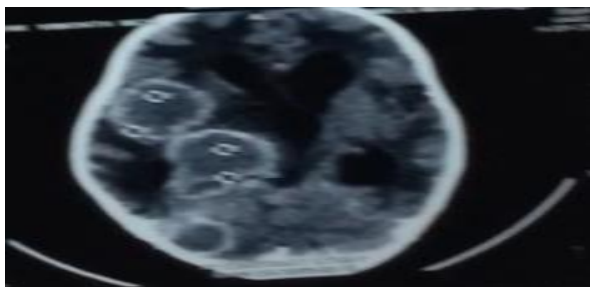


Fig. 3: Multiple tuberculoma on CT scan brain

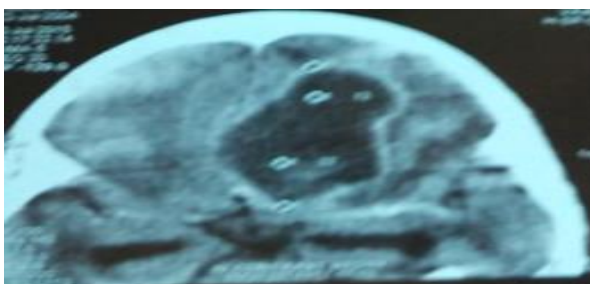

Fig. 4: Large brain abscess on CT scan of brain

Table 1: Age and gender distribution of subjects (n=42)

Age in Years	Female	Male	Total
	n (%)	n (%)	n (%)
5-8 years	3 (37.5%)	5 (62.5%)	8 (19%)
9-12 years	6 (42.9%)	8 (57.1%)	14 (33.3%)
>12 year	7 (35%)	13 (65%)	20 (47.7%)
Total	16 (38.1%)	26 (61.9%)	42 (100%)

Table 2: Types of lesions in different age groups (n=42)

Etiology	5 – 8 years	9 -12 years	>12 years	Total
Tuberculoma	3 (18.7%)	5 (31.3%)	8 (50%)	16 (38%)
NCC	2 (14.3%)	5 (35.7%)	7 (50%)	14 (33.3%)
Brain abscess	2 (25%)	2 (25%)	4 (50%)	8 (19.1%)
Brain tumors	0 (0%)	1 (50%)	1 (50%)	2 (4.8%)
Others	1 (50%)	1 (50%)	0 (0%)	2 (4.8%)
Total	8 (19%)	14 (33.3%)	20 (47.6%)	42 (100%)

Table 3: Location of lesions in brain (n=42)

Lesion	Frontal	Parietal	Temporal	Post. Fossa
Tuberculoma(16)	4 (25%)	8 (50%)	2 (12.5%)	2 (12.5%)
NCC (14)	5 (35.8%)	6 (42.8%)	2 (14.3%)	1 (7.1%)
Brain abscess (8)	2 (25%)	1 (12.5%)	5 (62.5%)	0 (0%)
Brain tumor (2)	0 (0%)	0 (0%)	0 (0%)	2 (100%)
Others (2)	0 (0%)	1 (50%)	1 (50%)	0 (0%)
Total (42)	11 (26.1%)	16 (39.2%)	10 (23.8%)	5 (11.9%)

## Discussion

Although secondary seizure with ring enhancing lesions is a novel phenomenon in developing countries like India, the volume of literature is sparse. In spite of attaining the magnitude of a public health menace, scientific studies are a few in number. In South India, infections of the CNS and single CT enhancing lesions accounted for 95% of the etiologies for seizure in children.<sup>(2)</sup>

Out of 42 cases in our study, 16 cases (38%) were female and 26 (62%) were male with a Male: Female ratio of 1.6:1. Most children belonged to the age group of >12 years. Youngest and eldest at presentation were 5.3 year 13.8 years respectively with a mean age of 11.2 years. Small children mostly remaining indoor were safe from risk factors and infections. Similarly, males being more exposed to outside environment and contact with diseased people were prone for different diseases. Girls are also neglected in Indian scenario and seek less attention. Bhaskar A Reddy *et al*,<sup>(3)</sup> in their study of 50 cases of ring enhancing lesions, 42 boys (84%) outnumbered 8 girls (16%) with majority (64%) of children in the age group of 6 to 10 years.

Seizure was the presenting feature in all 42 (100%) subjects. Headache was noted in 24 (57.1%) cases and vomiting in 22 (52.4%) cases. 6 cases (14.3%) complained of progressive vision loss. The various seizures observed were generalized in 66.6%, partial seizures in 28.6% and unexplained types in 4.7% cases.

Hypertension and bradycardia as signs of raised ICT were detected in 16 cases (38.1%) and cranial nerve palsy in 2 cases (4.8%). Papilloedema was detected in 14 (33.3%) and decreased visual acuity in 8 cases (19%). In the study by Bhaskar A Reddy *et al*<sup>(3)</sup> commonest clinical presentation was seizure in 94% of cases. Seizure, as the commonest mode of presentation of NCC was well reported from various studies with the incidence ranging from 22% to 96%.<sup>(4)</sup> Clinical signs vary with the size of the lesion. V. Karla study showed raised ICT was the commonest sign (91%) followed by seizure at the time of presentation.<sup>(5)</sup> Seizures patterns observed were similar to studies by Rajashekar's<sup>(6)</sup> and Mohd Ashraf *et al*.<sup>(7)</sup> Out of all the type of lesions, tuberculoma was the commonest (38%) in all age groups followed by neurocysticercosis (33%), brain abscess (20%), brain tumor (4.8%) and undiagnosed lesions (4.8%). In contrast, Bhaskar A Reddy *et al*<sup>(3)</sup> found 63.4% children as neurocysticercosis and only 9.7% children with tuberculoma. In developing countries, most of these ring enhancing lesions are caused by neurocysticercosis or tuberculosis with poor differentiating features between the two. This is because the clinical and imaging features are mostly similar. *Tuberculomas tend to be larger than 20 mm in diameter, have an irregular outline, cause more mass effect and have a progressive focal deficit, whereas cysts tend to be <20 mm in diameter, have a smooth regular outline and seldom cause progressive focal neurologic deficits.*<sup>(8)</sup>

Hemiparesis was the commonest type of focal neurological deficit (44.5%) followed by monoparesis (33.3%) in our study. Majority of tuberculomas (87.5%), neurocysticercosis (93%) and brain abscesses (87.5%) were associated with abnormal EEG. Focal discharges were seen in neurocysticercosis, but spike and wave patterns were common in tuberculomas. Majority of seizures in cases with tuberculoma were generalized (n=10, 62.5%) while generalized and focal seizures were equally prevalent in cases of neurocysticercosis. A study done by Mohd Ashraf *et al*,<sup>(7)</sup> the EEG was abnormal in 69.8% of generalized seizures, 64.7% in partial seizures and 1% in undetermined seizures of ring enhancing lesions.

Type of ring enhancing lesion determines its location in most instances. Nearly 50% of tuberculomas and neurocysticercosis lesions in our study were detected in parietal lobes whereas brain abscesses were mostly confined to temporal lobes like the study done by Mall Agrawal A *et al*.<sup>(9)</sup> Among tuberculoma lesions, 13 (81.2%) were found to be solitary and one was multiple (6.3%). In contrast, out of all neurocysticercosis cases 7 (50%) were multiple and 5 (35.7%) were solitary lesions. Baring one, all brain abscesses (n=7, 87.5%) and brain tumors were also solitary. Multiplicity can't confirm any type of lesion as all lesions can be single or multiple types. In Bhaskar A Reddy study, 82% children had single ring enhancing lesions on the CT scan of brain, 9.38% presented with 2 lesions and 9.37% had 3 or more lesions.<sup>(3)</sup> In Wendy G. Mitchell study, neurocysticercosis was solitary in 39 patients and multiple in 13 patients.<sup>(10)</sup>

Contact history to an open case of tuberculosis could be traced in 12 (75%) cases of tuberculoma. 7 cases (43.7%)

showed Positive Mantoux test and 5 children (31.2%) showed AFB in gastric aspirate and/or sputum. 11 children (68.7%) had BCG scar. There is evidence of pulmonary disease in 60% cases of tuberculoma.<sup>(11)</sup> Wadia R S et al found that out of 39 cases with ring enhancing lesions, 10 (25.6%) had evidence of tuberculosis in lungs or elsewhere in the body, 3 also had history of contact with tuberculosis.<sup>(12)</sup>

Common pathological agents of brain abscess found were *Streptococcus pyogenes*, *Pseudomonas* and *Klebsiella*.

After treatment of 42 cases, 24 (57.1%) got cured, 12 (28.6%) died and 6 children (14.3%) survived with sequelae. Out of 12 deaths, 3 each were from tuberculoma and neurocysticercosis group, 2 each from brain abscess and undiagnosed group and all 2 cases of brain tumor group.

### Conclusion

Common causes of symptomatic epilepsy in 5-14 years age group with ring enhancing lesion on neuroimaging are tuberculoma followed by neurocysticercosis and brain abscess which can be diagnosed by careful history, thorough clinical examination and appropriate investigations to plan for timely treatment for favorable outcome.

### Reference

- Hirtz D, Ashwal S, Berg A et al. Practice parameter: evaluating a first non-febrile seizure in children: report of the quality standards subcommittee of the American Academy of Neurology, The Child Neurology Society, and The American Epilepsy Society. *Neurology* 2000;55:616-623.
- Murthy JM, Yangala R. Acute symptomatic seizures- Incidence and aetiological spectrum: a hospital-based Study from South India. *Seizure* 1999;8(3):162-5.
- Reddy BA, Chitgope R, Roa SNN, Eluzai Z, Mugadlimath AB, Sane MR. A study of clinical presentation and etiology of ring enhancing lesions in computerized tomography (CT) scan brain in children. *IJMPS*. 2014;4(7):01-03.
- Arseni C Crislesene & epilepsy due to cerebral cysticercosis *Epilepsia* 1972;13:253-258.
- V. Kalra, Neurocysticercosis in childhood, *Tran. Of the Royal Society of Tropical Medicine & Hygiene*, 1987;81:371-373.
- V Rajashekar etiology & management of single small CT lesion in patients with epilepsy understanding controversy, *Acta Neurol Scand*. 84:465-470,1991.
- Ashraf M et al; Computed tomographic study in young epileptics in Kashmir, India *Al Ameen J Med Sci*; Volume 6, No.3, 2013.
- Garg RK. Diagnostic criteria for neurocysticercosis: some modifications are needed for Indian patients. *Neurol India* 2004;52:171-7.
- Mall, Agrawal A, Garg RK, Kar AM, Shukla R Short course of prednisolone in Indian patients with solitary cysticercus granuloma and new-onset seizures. *Epilepsia* 2003;44:1297-401.
- Wendy G. Mitchell, Intra parenchymal cerebral cysticercosis in children *Diagnosis management. Paediatrics*. 1988;82:76-82.
- Adair, J.C., Beck, A.C., Apfelbaum, R.I. and Baringer, R. Nocardial cerebral abscess in acquired immunodeficiency syndrome. *Arch. Neurol*. 1987;44,540.
- Sethi PP, Wadia RS, Kiyawat DP et al. Ring or disc enhancing Lesions in epilepsy in India. *J Trop Med Hyg* 1994;97(6):347-53.