

Rapidly growing brain tumor in a newborn considered to be teratoma: A rare case report

Shyama Choudhary¹, Niranjan Nagaraj^{2,*} Pramod Kumar Berwal³, Satyendra Khicher⁴

^{1,2}Senior Resident, ³HOD & Professor, Dept. of Paediatrics, ⁴Senior Resident, Dept. of Medicine, Sardar Patel Medical College, Rajasthan

***Corresponding Author:**

Email: getniranjan806@yahoo.com

Abstract

Teratomas constitute approximately 0.2% of all intracranial tumors.^[1] They mostly occur in children during the first decade and grow frequently in the midline region.^[3] Here, we report a rare case of posterior fossa immature teratoma in a 10 days old newborn delivered by normal vaginal delivery who presented with progressive enlargement of head. A magnetic resonance imaging (MRI) study showed a large mixed solid cystic lesion with in bilateral hemisphere posterior to third ventricle and in posterior fossa with obstructive hydrocephalus. Cerebrospinal fluid revealed marked elevation of the alpha-fetoprotein level and mild increase of the human chorionic gonadotropin level, strongly suggestive of teratoma. His activity began to deteriorate on postnatal day 18 and he died of respiratory distress on the 21st day of life.

Access this article online	
Quick Response Code:	Website: www.innovativepublication.com
	DOI: 10.5958/2455-6793.2016.00003.1

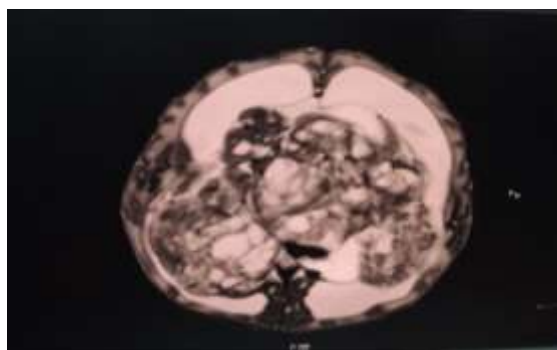
Spasticity of all 4 limbs and ankle clonus was present. A magnetic resonance imaging (MRI) study showed a large solid cystic lesion with hemorrhagic component (hyper intense on T1 and blooming on GRE sequences) in bilateral hemisphere posterior to third ventricle and in posterior fossa with approximate size 82*110*102 mm compressing over bilateral lateral and third ventricles with their dilatation [Fig. 1]. The tumor strongly enhanced with gadolinium and was multiloculated. Examination of cerebrospinal fluid revealed marked elevation of the alpha- fetoprotein level (12292 ng/ml) with mild increase of the human chorionic gonadotropin level (9.2 mIU/ml), strongly suggestive of teratoma. His activity began to deteriorate on postnatal day 18 and apnea developed. The infant died on the 21st day of life. His parents refused to permit autopsy of their son.

Introduction

Congenital central nervous system tumors are uncommon, accounting for 0.5–1.5% of all childhood brain tumors⁽¹⁾. The most common histological type is teratoma; present in one-third to one- half of all cases, followed by medulloblastoma, astrocytoma, choroid plexus papilloma, and ependymoma.^(2,3) Massive congenital intracranial teratoma is a rare neoplasm with poor prognosis because the tumor tissue has already replaced most of the brain tissue before first identification on fetal ultrasonography.⁽¹⁻⁵⁾ We here report a case of massive immature intracranial tumor of posterior fossa showing rapid growth that replaced most of the brain of a live newborn which was most probably teratoma as endoscopic biopsy was denied by patient's relatives.

Case Report

A ten days old baby born as a full-term to a 21-year primigravida by normal vaginal delivery without perinatal complications presented with rapid head enlargement. Infant was macrocephalic with a normal appearing body. Head circumference was 42.5cm (Above 95th percentile). Physical examination revealed bulging anterior fontanel 8 × 10 cm in diameter and bossing of the forehead. On examination, the baby was lethargic and found to have setting sun sign in eyes and prominent veins over forehead and sutural diastasis.



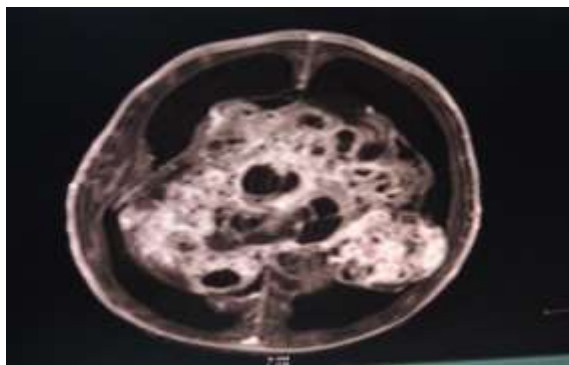


Fig. 1: Magnetic resonance images showed a large solid cystic lesion with hemorrhagic component in bilateral hemisphere posterior to third ventricle and in posterior fossa with approximate size 82*11*102 mm compressing over bilateral lateral and third ventricles with their dilatation

Discussion

Teratomas constitute approximately 0.2% of all intracranial tumors^[1] and 1.2–5% of intracranial tumors in children. The common pathologies being astrocytoma in 36%, medulloblastoma in 30%, ependymoma in 23%, followed by mixed neural-glioma tumor and atypical teratoid/rhabdoid tumor.^[1,2] They mostly occur in children during the first decade and grow frequently in the midline region including the pineal gland.^[3] Although it is often impossible to determine the exact site of origin, prenatally diagnosed intracranial teratomas are predominantly supratentorial, in contrast to their infratentorial location in older children.^[4,5] Although congenital intracranial teratomas producing hydrocephalus in early life are quite common, massive teratoma replacing almost the entire intracranial content of a neonate is an exceptionally rare event.^[5]

The majority of cases have been delivered by cesarean section because of abnormally large head size and difficult delivery. However, in several cases, vaginal delivery has been possible, occasionally with prior cranial decompression but in this case newborn was delivered by normal vaginal delivery. In majority of the reported cases, the outcome has been either stillbirth or death shortly after birth. Termination of the pregnancy has been recommended if the tumor is detected before the 24th week of gestation.^[6] Despite the benign histopathologic features of most intracranial teratomas, tumor growth is rapid, and the tumor frequently replaces all normal brain tissue resulting in massive craniomegaly.^[7] Size and favorable location is the most important determinant in the outcome regardless of the histologic classification as mature or immature.^[1]

The features revealed by ultrasound and CT include macrocrania in addition to alterations of the anatomical shape of the brain with or without calcifications and cysts. The differential diagnosis for a

sonographically diagnosed intracranial mass includes astrocytoma, ependymoma, craniopharyngioma, choroid plexus cyst, and intracranial hemorrhage. In our case, elevated CSF AFP, and findings on MRI at live day 15, such as large brain tumor of heterogeneous intensity and multiple cysts, led to diagnosis of immature teratoma

Treatment for viable cases includes radical surgical resection of the tumor, followed by either radiotherapy and/or chemotherapy. Endoscopic surgery is less invasive and easier to perform than open surgery, especially for histological examination of homogeneous lesions^[8]. If the patient survives, radiotherapy is usually postponed until 24 to 36 months of age to avoid complications such as stunted growth, endocrine disturbances, and neuropsychological problems. Prognosis of congenital intracranial teratoma is extremely poor, with a mortality rate around 90%.^[9] The prenatal diagnosis of intracranial teratoma is important for timely counseling of the parents and to aid in obstetrical decision making. It helps to prevent the mother from having further complications either due to intrauterine fetal death or psychological trauma of giving birth to a severely malformed baby. In the present case, the intracranial localization, enormous extension and size, and rapid progression of the tumor all combined to form a very poor prognosis.

References

- Schlembach D, Bornemann A, Rupprecht T, Beinder E. Fetal intracranial tumors detected by ultrasound: A report of two cases and review of the literature. *Ultrasound Obstet Gynecol* 1999;14:407-18.
- Rickert CH, Probst-Cousin S, Gullotta F. Primary intracranial neoplasms of infancy and early childhood. *Childs Nerv Syst* 1997;13:507-13.
- Jennings MT, Gelman R, Hochberg F. Intracranial germ-cell tumours: Natural history and pathogenesis. *J Neurosurg* 1985;63:155-67.
- Buetow PC, Smirniotopoulos JG, Done S. Congenital brain tumors: A review of 45 cases. *Am J Roentgenol* 1990;155:587-93.
- Odell JM, Allen JK, Badura RJ, Weinberger E. Massive congenital intracranial teratoma: A report of two cases. *Pediatr Pathol* 1987;7:333-40.
- Erman T, Gocer IA, Erdogan S, Gunes Y, Tuna M, Zorludemir S: Congenital intracranial immature teratoma of the lateral ventricle: a case report and review of the literature. *Neurol Res* 27:53–56,2005.
- Crussi FG. Intracranial teratomas. In: Crussi FG, editor. *Atlas of tumor pathology, Extragenital teratomas*. 2nd ed. Washington, D.C.: Armed Forces Institute of Pathology;1982. p. 155-6.
- Di Rocco F, Nonaka Y, Hamada H, Yoshino M, Nakazaki H, Oi S: Endoscopic biopsy interpretation difficulties in a congenital intracranial teratoma. *Childs Nerv Syst* 22:84–89, 2006.
- Isaacs H Jr. I. Perinatal brain tumors: A review of 250 cases. *Pediatr Neurol* 2002;27:249-61.