

Content available at: <https://www.ipinnovative.com/open-access-journals>

IP International Journal of Medical Paediatrics and Oncology

Journal homepage: <https://www.ijmpo.com/>

## Case Report

# Acute pancreatitis as a manifestation of multisystem inflammatory syndrome among children (MIS-C): A rare case

Kuruganti Vyshnavi Srividya<sup>1</sup>, Saiprasad Onkareshwar Kavthekar<sup>1</sup>,  
Suhās Panditrao Kulkarni<sup>1</sup>, V Chandra Teja<sup>1\*</sup>, Mohan Anantrao Patil<sup>1</sup>,  
Nivedita Balasaheb Patil<sup>1</sup>

<sup>1</sup>Dept. of Paediatrics, D.Y. Patil Medical College, D Y Patil Education Society (Deemed to be University), Kolhapur, Maharashtra, India



### ARTICLE INFO

#### Article history:

Received 13-04-2024

Accepted 27-04-2024

Available online 11-05-2024

#### Keywords:

Acute pancreatitis

Covid 19

Multisystem inflammatory syndrome among children (MIS-C)

### ABSTRACT

A multisystem inflammatory syndrome among children (MIS-C) has been linked to COVID-19, and it affects multiple organ systems in the body, including the gastrointestinal system. In present case report, a 14-year-old girl presented with clinico-laboratory and imaging evidence of acute pancreatitis but did not respond to the standard line of management for pancreatitis. Later, the laboratory investigations pointed to the diagnosis of MIS-C. She responded well to a pulse doses of methylprednisolone therapy. Acute pancreatitis as a lone manifestation of MIS-C poses a diagnostic challenge for paediatricians, and one should suspect MIS-C in acute non-responding pancreatitis.

This is an Open Access (OA) journal, and articles are distributed under the terms of the [Creative Commons Attribution-NonCommercial-ShareAlike 4.0 License](https://creativecommons.org/licenses/by-nc-sa/4.0/), which allows others to remix, tweak, and build upon the work non-commercially, as long as appropriate credit is given and the new creations are licensed under the identical terms.

For reprints contact: [reprint@ipinnovative.com](mailto:reprint@ipinnovative.com)

## 1. Introduction

The year 2020 is known for the global pandemic due to COVID-19, which is caused by SARS-CoV-2.<sup>1</sup> Multisystem Inflammatory Syndrome among Children (MIS-C), a notable inflammatory response, showed a temporal connection with the COVID-19 pandemic, typically presenting in the setting of prior or recent infection by this virus and may present with multiorgan dysfunction, myocarditis, shock, and rarely death.<sup>2,3</sup> MIS-C presenting as a sole manifestation of acute pancreatitis has been documented in very few case studies, shedding light on the potential mechanisms by which the virus may induce pancreatic inflammation.<sup>4-6</sup> In present case report, we report a 14-year-old girl who presented with acute pancreatitis and did not respond to the standard line of management but later turned out to be a manifestation of

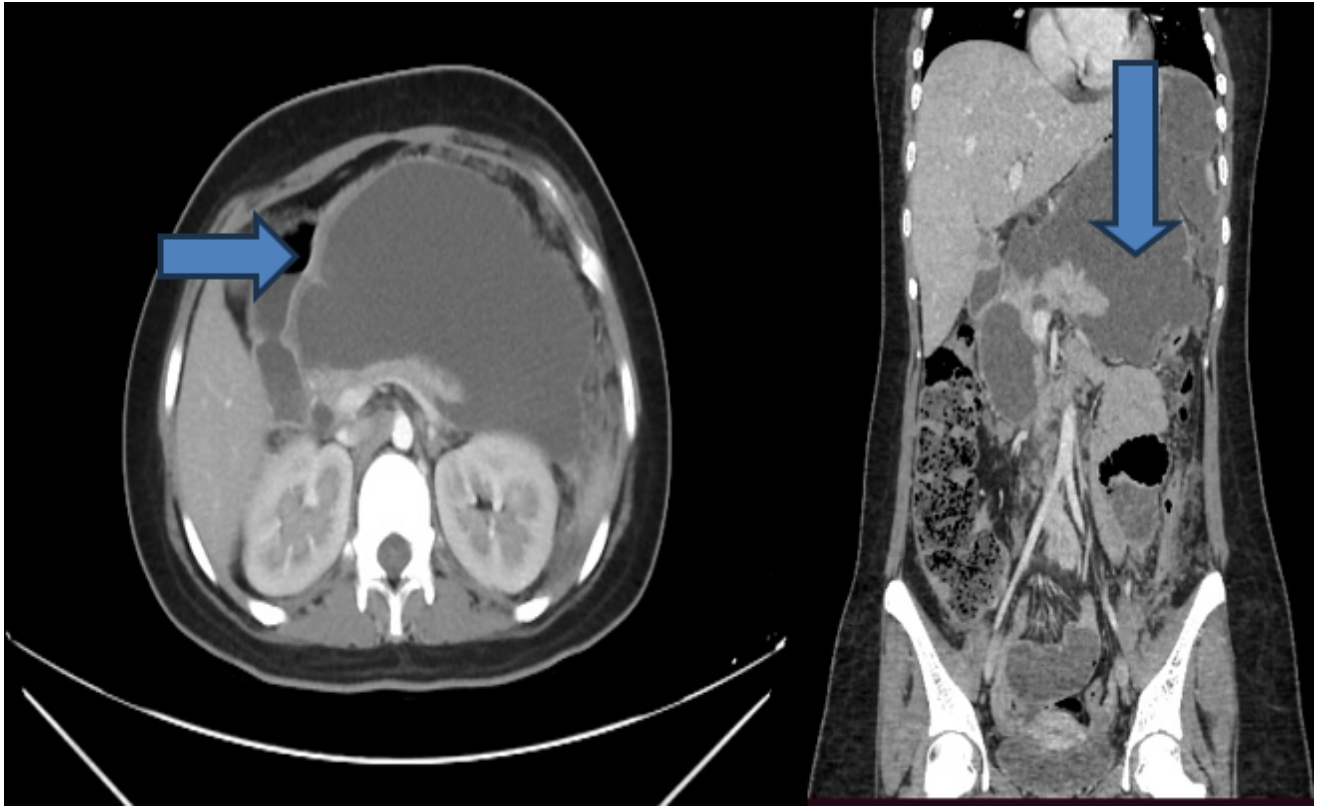
MIS-C.

## 2. Case Report

A 14-year-old girl presented in April 2023 with chief complaints of fever, severe epigastric pain, and vomiting since last 5 days. She was treated with analgesics, antiemetics, and antibiotics by a local physician. But her symptoms worsened, and she was referred to our tertiary care hospital for further management. On examination, she was febrile, sick-looking, and in a shock state with abdominal distension and rebound tenderness throughout the abdomen. Positive Rovsing's and Psoas signs were also observed. Subsequent abdominal ultrasonography and abdominal CT scans revealed acute pancreatitis with moderate ascites [Figure 1] and bilateral pleural effusion. The laboratory investigations showed elevated white cell counts with predominant neutrophilia, serum lipase (832 U/L) and serum amylase (972 U/L), blood urea (47.4

\* Corresponding author.

E-mail address: [vchandrteja27@gmail.com](mailto:vchandrteja27@gmail.com) (V. C. Teja).



**Figure 1:** Abdominal CT scan showing acute pancreatitis with ascites

mg/dL), deranged liver function tests and hyponatremia.

The patient was initially treated with the diagnosis of acute pancreatitis with intravenous fluid bolus and maintenance doses, broad-spectrum antibiotics like vancomycin, meropenem, and metronidazole in appropriate doses. Supportive treatments like oxygen therapy, tramadol, and pantoprazole were also administered. As there was persistence of fever and shock, inotropes were also added in view of septic shock, but the patient still did not respond, and her condition worsened. Considering possible other aetiologies and diagnosis, we sent her inflammatory markers. Her CRP, D-dimer, LDH, and serum ferritin were 232 mg/dl, 9610 ng/L, 933 IU/L, and 535, respectively. Then the COVID antibodies were also sent and came positive with a titre of 15.50, while the RTPCR for COVID-19 was negative.

In view of fever for more than five days, gastrointestinal manifestation in the form of acute pancreatitis, highly elevated inflammatory markers, and positive COVID antibodies, a diagnosis of MIS-C was considered. Injection Methylprednisolone was started in pulse doses of 30 mg/kg/day for five days as the patient was not affordable for injection intravenous immunoglobulin, which is considered to be the first line treatment for MIS-C. Within two days, there was a significant improvement in vitals along with the general and systemic condition of the

patient. Subsequently, her inflammatory markers subsided, and abdominal ultrasonography showed a regression of pancreatic inflammation. The patient showed clinical improvement over time, with a gradual transition to a liquid-to-solid diet, and was discharged after 10 days.

### 3. Discussion

Multisystem inflammatory syndrome in children (MIS-C) is a serious condition that appears to be linked to the coronavirus disease 2019 (COVID-19). Most children who become infected with the COVID-19 virus have only a mild illness, but in children who go on to develop MIS-C, organs like heart, lungs, blood vessels, kidneys, digestive system, brain, skin, or eyes become severely inflamed along with raised laboratory markers of inflammation.<sup>2</sup>

While for the diagnosis of acute pancreatitis, a minimum two of the three criteria are required: 1. Abdominal pain 2. Serum amylase or lipase > 3 times the upper normal limit and 3. Characteristic findings on diagnostic imaging.<sup>7</sup> Our patient had all the characteristic features of MIS-C, as well as all the clinical, laboratory, and imaging findings for the diagnosis of acute pancreatitis. Our patient responded very well to injection methylprednisolone therapy, which was also suggestive of a diagnosis of MIS-C.

A similar case report was published by Vijay P et al. with large necrotizing pancreatitis with walled-off pancreatic necrosis in MIS-C, which required surgical intervention<sup>4</sup>. The virus's ability to bind to ACE2 receptors expressed in respiratory epithelial cells and pancreatic tissue suggests a direct viral involvement in pancreatic injury. This aligns with the notion that the pancreas may serve as a target organ for viral invasion, leading to an inflammatory cascade and the subsequent development of acute pancreatitis.<sup>8</sup> The systemic inflammatory response could be the reason for the pancreatic insult in MIS-C.

#### 4. Conclusion

Acute pancreatitis as a lone manifestation of MIS-C poses a diagnostic challenge for pediatricians and one should suspect for MIS-C in acute non-responding pancreatitis.

#### 5. Source of Funding

None.


#### 6. Conflict of Interest


None.

#### References

1. Holshue ML, DeBolt C, Lindquist S, Lofy KH, Wiesman J. First case of 2019 novel coronavirus in the United States. *N Engl J Med*. 2020;382(10):929–36.
2. Centre for Disease Control and Prevention. 2021. Multisystem Inflammatory Syndrome in Children (MIS-C). [Accessed 1 July 2023]. Available from: <https://www.cdc.gov/mis-c/index.html>.
3. Cheung KS, Hung IFN, Chan PPY, Lung K, Tso E, Liu R, et al. Gastrointestinal Manifestations of SARS-CoV-2 Infection and Virus Load in Fecal Samples From a Hong Kong Cohort: Systematic Review and Meta-analysis. *Gastroenterology*. 2020;159(1):81–95.
4. Vijay P, Gupta RK, Madaan A, Gupta ML. COVID-19 Associated Multisystem Inflammatory Syndrome in Children Presenting as Acute Necrotizing Pancreatitis with Walled-off Pancreatic Necrosis (WOPN). *J Pediatr Gastroenterol Nutr*. 2023;5(2):60–2.
5. Giannattasio A, Maglione M, Anna D, Muzzica C, Pappacoda S, S. Liver and Pancreatic Involvement in Children with Multisystem Inflammatory Syndrome Related to SARS-CoV-2: A Monocentric Study. *Children (Basel)*. 2022;9(4):575. doi:10.3390/children9040575.
6. Bana SK, Deswal S, Mohan N. Acute severe necrotizing pancreatitis: a manifestation of multisystem inflammatory in children? *Indian Pediatr Case Rep*. 2021;1(1):162–5.
7. Banks PA, Bollen TL, Dervenis C, Gooszen HG, Johnson CD, Sarr MG, et al. Classification of acute pancreatitis–2012: revision of the Atlanta classification and definitions by international consensus. *Gut*. 2013;62(1):102–11.
8. Liu F, Long X, Zhang B, Zhang W, Chen X, Zhang Z, et al. ACE2 expression in pancreas may cause pancreatic damage after SARS-CoV-2 infection. *Clin Gastroenterol Hepatol*. 2020;18(9):2128–30.

#### Author biography

**Kuruganti Vyshnavi Srividya**, Junior Resident  <https://orcid.org/0009-0001-8272-1818>

**Saiprasad Onkareshwar Kavthekar**, Professor  <https://orcid.org/0000-0003-0467-4275>

**Suhas Panditrao Kulkarni**, Professor

**V Chandra Teja**, Junior Resident  <https://orcid.org/0009-0003-6012-0768>

**Mohan Anantrao Patil**, Professor

**Nivedita Balasaheb Patil**, HOD  <https://orcid.org/0000-0002-5395-8234>

**Cite this article:** Srividya KV, Kavthekar SO, Kulkarni SP, Teja VC, Patil MA, Patil NB. Acute pancreatitis as a manifestation of multisystem inflammatory syndrome among children (MIS-C): A rare case. *IP Int J Med Paediatr Oncol* 2024;10(1):25-27.