

Content available at: <https://www.ipinnovative.com/open-access-journals>

IP International Journal of Medical Paediatrics and Oncology

Journal homepage: <https://www.ijmpo.com/>

## Case Report

# Management of anterior crossbite using various treatment modalities

Arushi Goel<sup>1</sup>, Khushboo Barjatya<sup>1,\*</sup>, Pankhuri Bagzai<sup>1</sup>, Farah Manager<sup>1</sup>

<sup>1</sup>Dept. of Pediatric and Preventive Dentistry, Sri Aurobindo College of Dentistry, Indore, Madhya Pradesh, India



### ARTICLE INFO

#### Article history:

Received 19-04-2023

Accepted 29-06-2023

Available online 12-07-2023

#### Keywords:

Anterior cross bite

Interceptive Orthodontics

Trauma from occlusion

### ABSTRACT

**Background:** Anterior crossbite is the term used to define an occlusal problem involving palatal positioning of the maxillary anterior teeth relative to the mandibular anterior teeth. It has a reported incidence of 4-5% and is usually the result of a palatal malposition of the maxillary incisors resulting from a lingual eruption path.

**Case Series:** Three male patients reported to the department of pediatric and preventive dentistry, Sri Aurobindo College of Dentistry with the chief finding of anterior cross bite were treated with different fixed and removable treatment modalities.

**Conclusion:** During the early correction of simple and minor malocclusions, which is a part of interceptive orthodontic treatment, the anterior cross-bite is corrected more rapidly & it is achieved by removable appliances or fixed appliances.

This is an Open Access (OA) journal, and articles are distributed under the terms of the [Creative Commons Attribution-NonCommercial-ShareAlike 4.0 License](https://creativecommons.org/licenses/by-nc-sa/4.0/), which allows others to remix, tweak, and build upon the work non-commercially, as long as appropriate credit is given and the new creations are licensed under the identical terms.

For reprints contact: [reprint@ipinnovative.com](mailto:reprint@ipinnovative.com)

## 1. Introduction

According to Ackerman and Proffit (1980) interceptive orthodontics can be defined as “elimination of existing interferences with the key factors involved in the development of the dentition.”<sup>1</sup> Anterior crossbite is the term used to define an occlusal problem involving palatal positioning of the maxillary anterior teeth relative to the mandibular anterior teeth. The aberrant axial inclination of the maxillary anterior teeth is the source of anterior dental crossbites, which can be either dental or skeletal in origin. The most typical cause of anterior skeletal crossbites is a skeletal issue such mandibular prognathism or midface deficit.<sup>2</sup>

The period of mixed dentition offers the greatest opportunity for occlusal guidance and interception of malocclusion.<sup>3</sup> If delayed to a later stage of maturity, treatment may become more complicated.<sup>4</sup> In order to

choose the best clinical course of action, it is crucial to differentiate between dental and skeletal anterior crossbite. This can be done by making an effort to bring the jaw into a centric connection and assessing the relationship between the incisors and molars. If the incisors are in an edge-to-edge relationship and the molars are in a Class I relationship, dental repair can be done.<sup>5</sup>

Anterior dental crossbite is known to occur in 4-5% of cases and is typically brought on by the maxillary incisors being positioned improperly in the mouth due to a lingual eruption path.<sup>6</sup> In order to prevent relapse, the afflicted maxillary tooth or teeth must be labially tipped to a stable overbite relationship as part of the treatment for anterior dental crossbite. A mandibular tooth’s lingual movement, a maxillary tooth’s labial movement, or both may be necessary during treatment.<sup>5</sup> To accomplish this, a variety of methods have been employed, including fixed appliances, removable acrylic appliances with lingual springs, reversed stainless steel crowns, composite inclined planes, and tongue blades.<sup>7-9</sup>

\* Corresponding author.

E-mail address: [khushboo.barjatya@gmail.com](mailto:khushboo.barjatya@gmail.com) (K. Barjatya).

## 2. Case Series

### 2.1. Case 1

A 9 year old male patient (Figure 1) reported to the Department of Paediatric and Preventive Dentistry of Sri Aurobindo College of Dentistry with the chief complaint of malocclusion in upper and lower front teeth. No relevant medical or dental history was given.

On intra-oral examination over-retained 51 and 61 were noted. 21 was rotated. Grossly decayed 54.(Figures 2, 3 and 4) Study models were prepared and radiographic examination was done.

Over-retained 51 and 61 were uneventfully extracted under local anesthesia. After considering clinical findings like crowding, rotation, and more permanent teeth in crossbite a modification of the 2x4 appliance, 2x 2 appliance was planned (bands placed on molars and brackets bonded on incisors).

#### 2.1.1. 2X2 Appliance

After discussing the treatment modalities with parents, treatment was initiated by cementing orthodontic molar bands with buccal tubes on permanent first molars on both sides. Metal brackets MBT with a 0.022" slot were bonded on the labial aspects of the maxillary central permanent incisors. A removable posterior bite plane was fabricated and given to the patient to wear at all the times except during meals. A nickel-titanium (Ni-Ti) 0.012" round archwire was placed into the bracket slots and then into the molar tube on both sides. The wire was stabilized in its position using elastic ties for 1 month (Figures 5, 6, 7 and 8 ) and retained for further another 1 month before debonding of the brackets (Figure 9). On one month follow up both the maxillary central incisors were noted in the labial position, out of the crossbite position. The 0.012" round Ni-Ti archwire was changed to the 0.014" round Ni-Ti archwire.(Figure 9)

At the 2-month review, the incisor teeth were in positive overjet. All four incisors had been aligned in the proper position will maintain the "Ugly Duckling Stage". (Figures 10 and 11)

### 2.2. Case 2

10Yr/male patient reported to the Department of Pediatric and Preventive Dentistry, of Sri Aurobindo College of Dentistry with the chief complaint of mobility in the lower front tooth. No relevant medical or dental history was given.

On Intra- Oral examination, it was noted that 21 was in crossbite with 41 causing grade 1 mobility with 41 due to trauma from occlusion.12 was rotated. Dental caries with 75 and 85, missing 74 and 84 with mild lower anterior crowding. (Figures 12, 13 and 14)

A comprehensive treatment plan was prepared to relieve trauma from occlusion by correcting the anterior crossbite. A removable Z spring appliance with a posterior bite plane

for the upper arch and Lingual Arch for the lower arch was planned. All required restorations were done before the initiation of the treatment (Figures 15, 16, 17 and 18).

Appliance re-activation was done at 3 weeks. No mobility noted with 42.1 month follow up was done.

At 2 months follow up both the central incisors were positioned labially, crossbite was corrected and trauma from occlusion was relieved. (Figures 19 and 20)

The lingual arch was recemented for space maintenance and z spring with posterior bite plane therapy was discontinued.

### 2.3. Case 3

#### 2.3.1. Catalance therapy

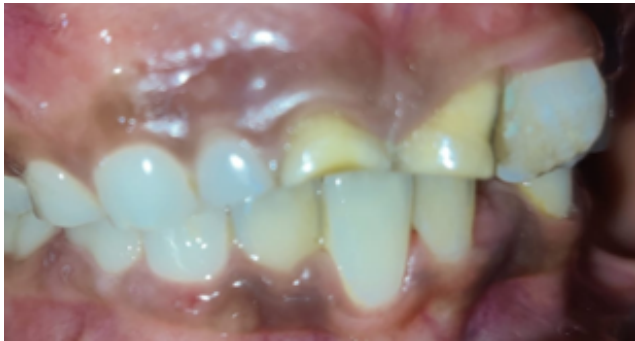A 7-year-old male patient reported to the Department of Pediatric and Preventive Dentistry with a complaint of palatally placed upper central incisors. A complete clinical examination revealed the permanent maxillary central incisor in crossbite along with initial demineralization with the upper and lower anterior.(Figure 21) Following clinical and radiographic examinations, the decision was made to fabricate an inclined plane. The parents were informed about the treatment plan before treatment was initiated.

An anterior bite plane appliance with an 45' angulation was fabricated.

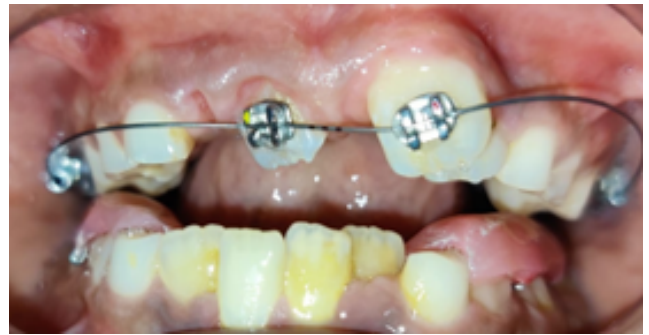The crossbite was corrected after the cementation of the Catlan's appliance within three weeks. Topical fluoride therapy was given to remineralize the initial demineralization.



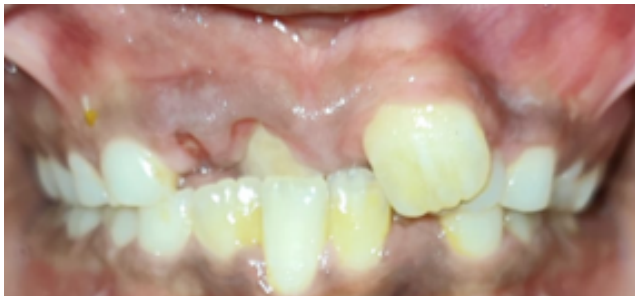Fig. 1:



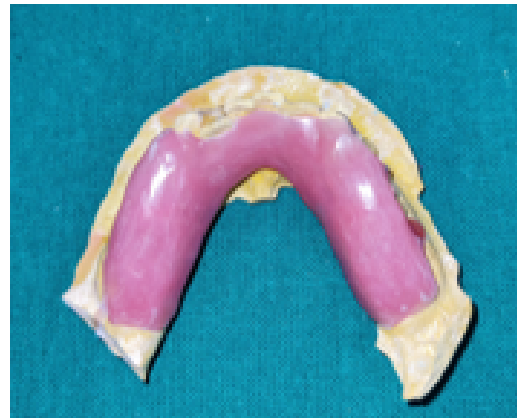**Fig. 2:**



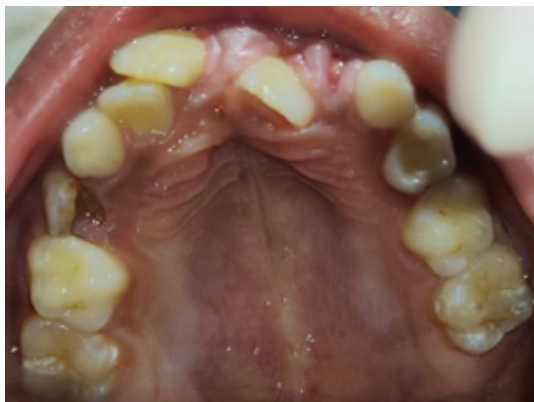**Fig. 6:**



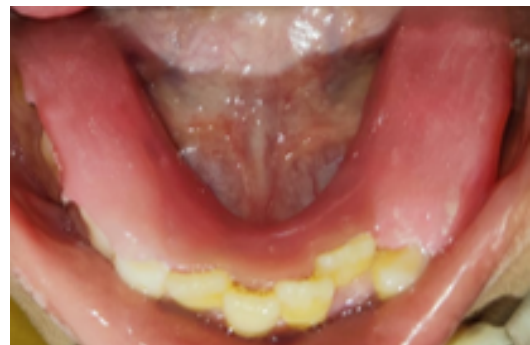**Fig. 3:**



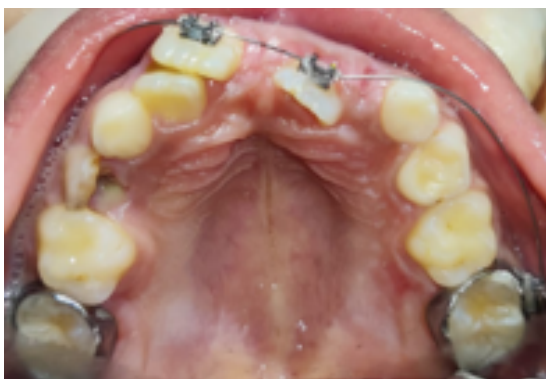**Fig. 7:**



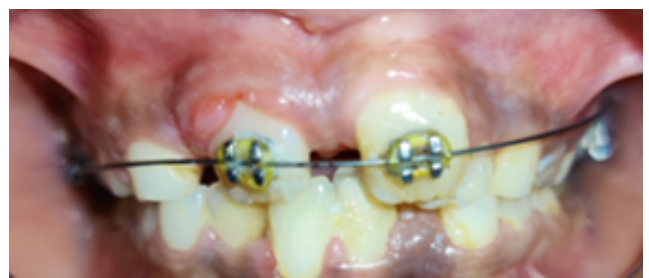**Fig. 4:**



**Fig. 8: Figure 8**



**Fig. 5:**



**Fig. 9:**

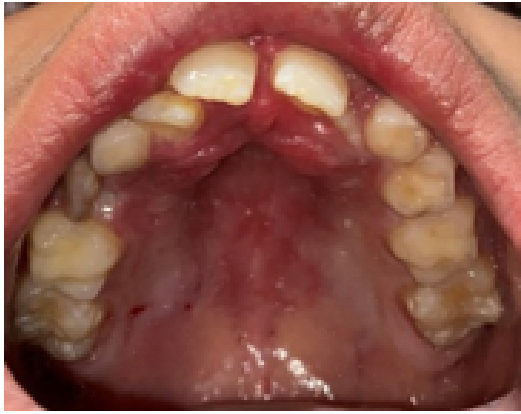

Fig. 10:

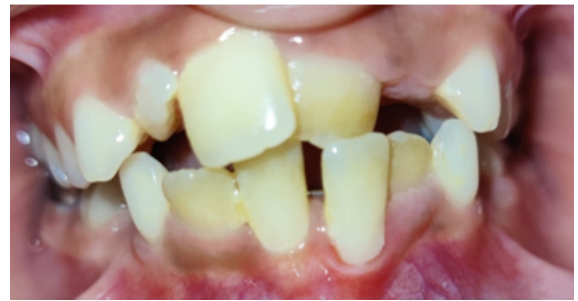

Fig. 14:

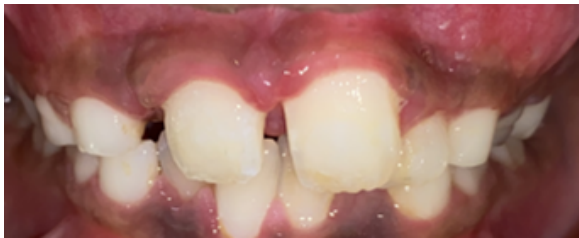

Fig. 11:

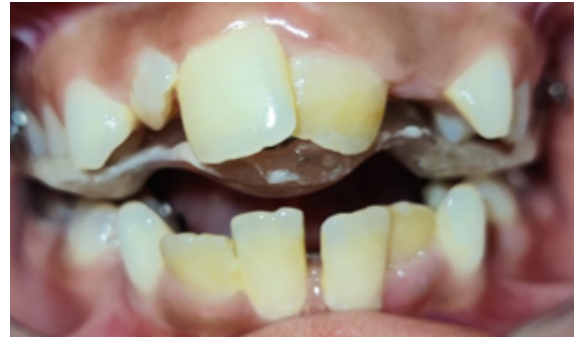

Fig. 15:

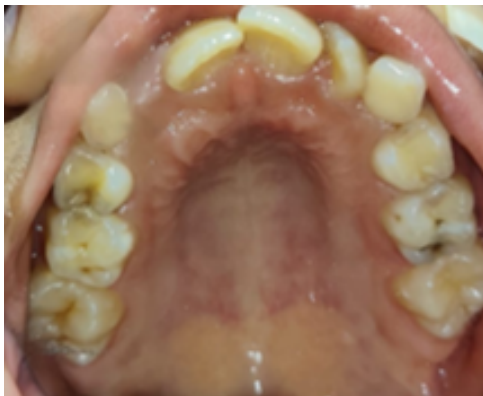

Fig. 12:

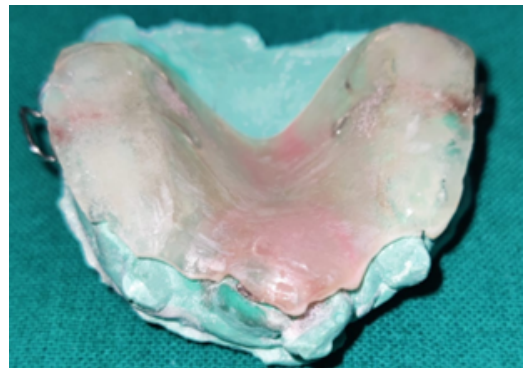


Fig. 16:

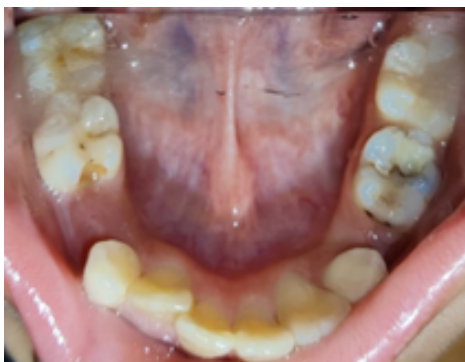

Fig. 13:

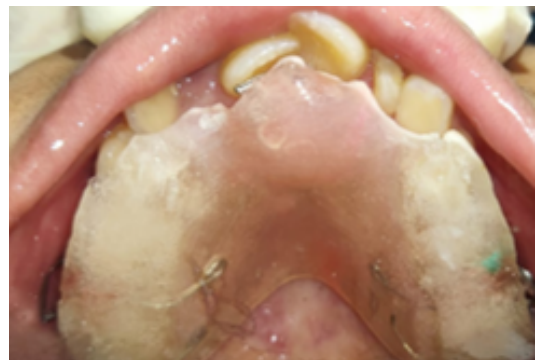

Fig. 17:

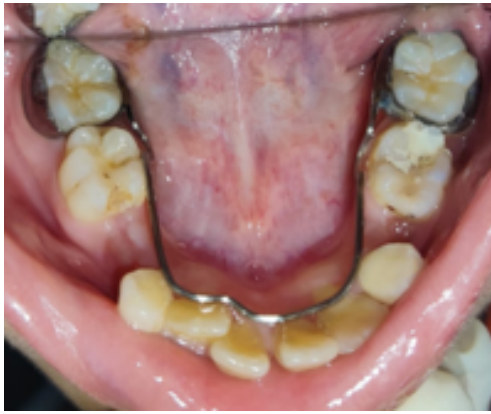

Fig. 18:

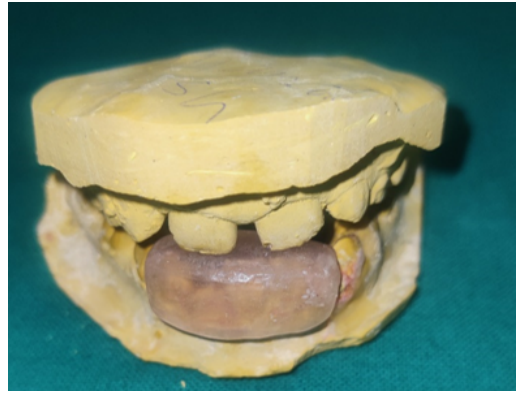

Fig. 22:

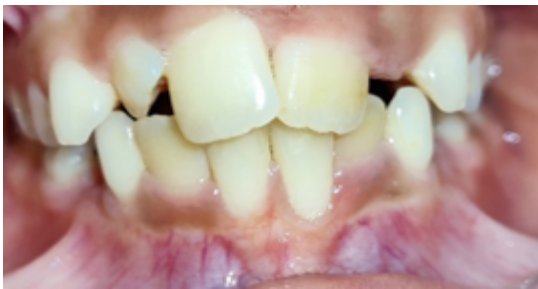

Fig. 19:

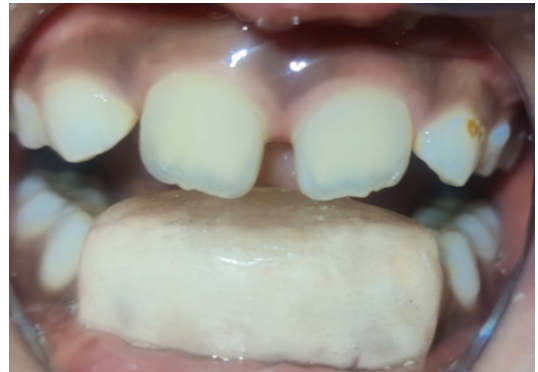

Fig. 23:

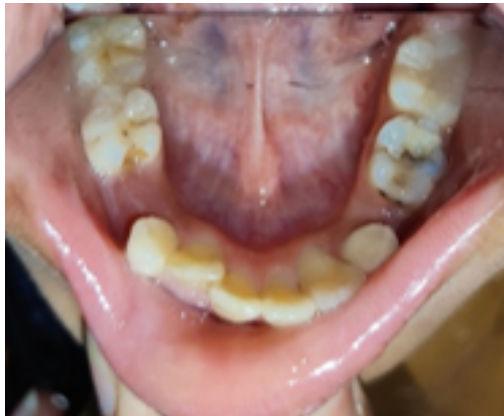

Fig. 20:

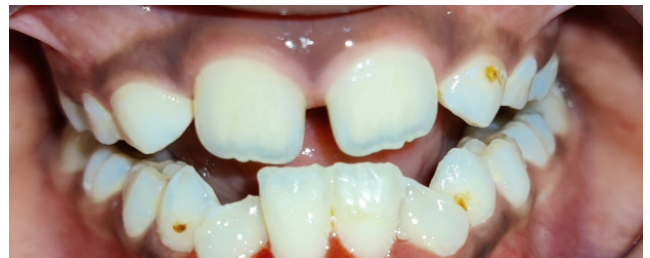

Fig. 24:

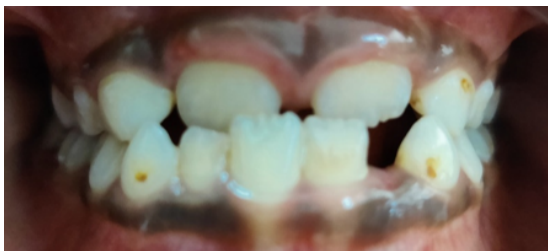

Fig. 21:

### 3. Discussion

Interceptive Approach: It incorporates all methods initiated to decrease the complexity of malocclusion to progress normal occlusion in the future.<sup>10</sup>

The aim of using removable or fixed appliances primarily for the prevention purpose is to attain:<sup>10</sup>

1. Good alignment of the permanent dentition.
2. To achieve harmony between dentition and aesthetics.
3. Stability between dental, muscular & skeletal components.
4. Dental arches with optimal intercuspation.

The ideal age to correct an anterior dental crossbite is between 8 and 11 years old because this is when the tooth's active period of eruption and root development takes place, according to a 2011 study by Prakash et al. Therefore, a child's age is quite important. The patient's motivations for seeking treatment and level of cooperation, however, must also be taken into account.<sup>10</sup>

According to Prakash Petal's study from 2011, the optimal age for correcting an anterior dental crossbite is between 8 and 11 years old because this is when the tooth's active period of eruption and root creation take place. As a result, a child's age is crucial. However, it's also crucial to consider the patient's reasons for seeking treatment and how well they cooperate.<sup>11</sup>

In some situations, a composite inclined bite plane is the first treatment option because it is an efficient, straightforward, and non-invasive technique. However, a composite plane cannot be used in cases where the anterior crossbite exceeds 1/3 the crown length. Moreover, the cement used with this type of appliance may cause gingivitis.<sup>12</sup>

For the treatment of an anterior crossbite, removable orthodontic appliances are yet another option that is secure, simple, and aesthetically pleasing. Because the appliances are made in a lab rather than the patient's mouth, less time is spent in the chair. Additionally, the appliances can be removed for socially awkward situations where having wires showing on the teeth's facial portion would be undesirable. Since the base plate is firm despite being divided into two halves by the acrylic appliances, the degree of desired movement of the teeth may be regulated by the screw, making management simple and reducing the chance of dislodgement. Fixed therapy is indicated in more complex cases where rotations are present. 2x 4 appliance is a common therapy used for the correction of anterior crossbite.<sup>13</sup> The modification 2x2 was found to be equally effective.

#### 4. Conclusion

Understanding the need of early diagnosis and correction is crucial. The anterior cross-bite was corrected more quickly during the early correction of simple and mild malocclusions, which is a part of interceptive orthodontic therapy, and it is accomplished by removable appliances or fixed appliances.

#### 5. Source of Funding

None.

#### 6. Conflicts of Interest

None.

#### References

1. Proffit WR, Fields HW, Larson B, Sarver DM. Contemporary orthodontics-e-book. Elsevier Health Sciences; 2018.
2. Moyers RE. Handbook of Orthodontics. Year Book Medical Publishers, Inc; 1973.
3. Kocadereli I. Early treatment of posterior and anterior crossbite in a child with bilaterally constricted maxilla: report of case. *ASDC J Dent Children*. 1998;65(1):41–6.
4. Tse CS. Correction of single-tooth anterior crossbite. *J Clin Orthod*. 1997;31(3):188.
5. Park JH, Kim TW. Anterior crossbite correction with a series of clear removable appliances: A case report. *J Esthet Restor Dent*. 2009;21(3):149–59. doi:10.1111/j.1708-8240.2009.00257.x.
6. Major PW, Glover K. Treatment of anterior cross-bites in the early mixed dentition. *J Can Dent Assoc*. 1992;58(7):574–5.
7. Vadiakas G, Viazis AD. Anterior crossbite correction in the early deciduous dentition. *Am J Orthod Dentofacial Orthop*. 1992;102(2):160–2. doi:10.1016/0889-5406(92)70029-A.
8. Kiyak HA. Patients' and parents' expectations from early treatment. *Am J Orthod Dentofacial Orthop*. 2006;129(4):50–4. doi:10.1016/j.ajodo.2005.09.018.
9. Fatima J, Jain P. A witty hand of orthodontic treatment- Fixed partial appliance. *J Appl Dent Med Sci*. 2015;.
10. Prakash P, Durgesh BH. Anterior Crossbite Correction in Early Mixed Dentition Period Using Catlan's Appliance: A Case Report. *ISRN Dent*. 2011;doi:10.5402/2011/298931.
11. Sari SA, Gokalp HA, Aras SA. Correction of anterior dental crossbite with composite as an inclined plane. *Int J Paediatr Dent*. 2001;11(3):201–8. doi:10.1046/j.1365-263x.2001.00256.x.
12. Croll TP, Riesenberger RE. Anterior crossbite correction in the primary dentition using fixed inclined planes. II. Further examples and discussion. *Quintessence Int*. 1985;19(1):45–51.
13. Donald M. Dentistry for the Child and Adolescent. 8th Edn. Elsevier, A division of Reed Elsevier India Pvt. Ltd.; 2005. p. 651–3.

#### Author biography

**Arushi Goel**, Post Graduate Student

**Khushboo Barjatya**, Professor and Guide

**Pankhuri Bagzai**, Post Graduate Student

**Farah Manager**, Post Graduate Student

**Cite this article:** Goel A, Barjatya K, Bagzai P, Manager F. Management of anterior crossbite using various treatment modalities. *IP Int J Med Paediatr Oncol* 2023;9(2):77-82.