

Content available at: <https://www.ipinnovative.com/open-access-journals>

IP International Journal of Medical Paediatrics and Oncology

Journal homepage: <https://www.ijmpo.com/>

## Case Report

# An atypical case of tracheoesophageal fistula with esophageal atresia- Case report

Gandra Abhinav<sup>1,\*</sup>, Kota Vamshi<sup>2</sup>, S. Narasimha Rao<sup>1</sup>

<sup>1</sup>Dept. of Paediatrics and Neonatology, Kamineni Academy of Medical Sciences & Research Centre, Hyderabad, Telangana, India

<sup>2</sup>Kamineni Academy of Medical Sciences & Research Centre, Hyderabad, Telangana, India



### ARTICLE INFO

#### Article history:

Received 20-11-2022

Accepted 23-11-2022

Available online 11-01-2023

#### Keywords:

Tracheoesophageal fistula

Esophageal atresia

### ABSTRACT

Tracheoesophageal fistula (TEF) with Esophageal atresia (EA) is a rare congenital malformation, incidence of 1 in 3500 live births. TEF presents usually in a neonate on day 1 of life with respiratory distress, copious secretions, cyanosis, difficulty in passing Nasogastric tube along with antenatal history of polyhydramnios. A high index of suspicion is required for early diagnosis and management, to decrease the severity and morbidity and thereby preventing long term implications on neurological development. Currently, Survival rates surpassed 90% due to surgical advances, specialized anesthetic care, NICU care. However, there is a rise in TEF morbidity, partly secondary to the surgical repair or intrinsic to anatomical anomaly. Here, we described a case of a neonate admitted to Kamineni academy of medical sciences with a atypical presentation of Tracheoesophageal fistula who responded well to treatment.

This is an Open Access (OA) journal, and articles are distributed under the terms of the [Creative Commons Attribution-NonCommercial-ShareAlike 4.0 License](https://creativecommons.org/licenses/by-nc-sa/4.0/), which allows others to remix, tweak, and build upon the work non-commercially, as long as appropriate credit is given and the new creations are licensed under the identical terms.

For reprints contact: [reprint@ipinnovative.com](mailto:reprint@ipinnovative.com)

## 1. Introduction

EA/TEF is a life-threatening condition, however, the majority of affected infants will recover fully if the defect is detected early and treated appropriately.<sup>1</sup> EA/TEF is present at birth (congenital). EA and TEF affect males and females in equal numbers. The majority of cases are sporadic /non-syndromic. Familial (syndromic) cases account for less than 1 percent of all cases. VATER association is a specific pattern of multiple congenital malformations<sup>2</sup> and was first described in 1972 by Quan and Smith as a non-random co-occurrence of Vertebral anomalies, Anal atresia, Tracheoesophageal fistula and/or Esophageal atresia, Radial dysplasia. The original acronym VATER has been widened into VACTERL, including Cardiovascular, Renal and Limb anomalies associated with the former ones.<sup>3-6</sup>

Because of the high clinical variability and sporadic occurrence, the etiology of VACTERL association is still unclear and a precise etiological cause has been identified just in a small fraction of patients so far. EA/TEF can occur as isolated findings (nonsyndromic), associated with other birth defects (non-isolated), or as part of a larger syndrome. Here, we described a case of a neonate admitted to Kamineni academy of medical sciences with atypical presentation of Tracheoesophageal fistula, explaining the need for suspicion of this complex disease even without the classical presentation.

## 2. Case Report

A 39 4/7 week term female neonate born by Cesarean section with 2.67 kg birth weight. Baby presented with copious, white frothy secretions and difficulty in breathing on the first day of life.

\* Corresponding author.

E-mail address: [abhinavgandra@gmail.com](mailto:abhinavgandra@gmail.com) (G. Abhinav).

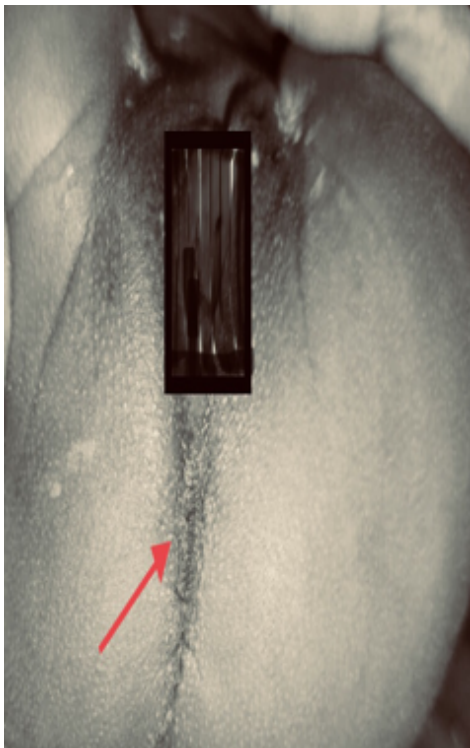
### 2.1. Antenatal history

A 28 years old Primi with 39+4 weeks of Gestational age conceived spontaneously. Dating scan done and dates assigned. TIFFA scan was suggestive of Single umbilical artery. Growth scan showed adequate Amniotic fluid index of 9cm. No other comorbidities, Negative serologies.

### 2.2. Birth history

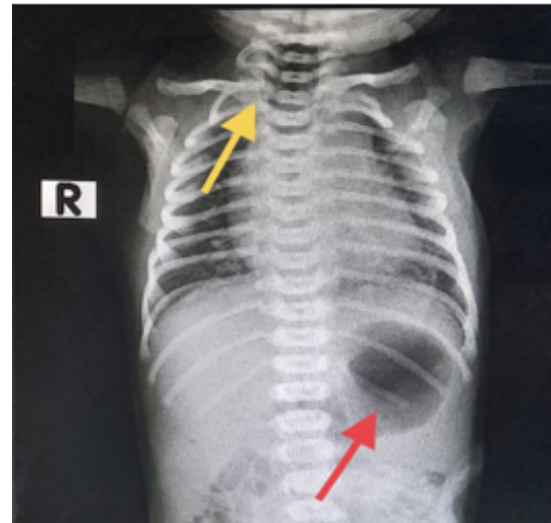She delivered a Term, female baby with birth weight of 2.77 kgs via Emergency LSCS i/v/o non progression of labour. Baby cried immediately after birth. APGAR was 7/10 at 1min and APGAR 8/10 at 5min. Cord ABG was normal with pH:7.34, pCo<sub>2</sub>:33, Hco<sub>3</sub>: 17.5, Base: -6.8.

Baby presented with copious, white frothy secretions and difficulty in breathing at delivery. Baby was admitted to NICU In view of respiratory distress and for further evaluation. On examination, Baby was Euthermic, Temp :36.5 c, HR :152/min, RR:62/min, Blood pressure :72/43(51)mm hg, Spo<sub>2</sub>:99% on CPAP support, CVS:S1S2 heard, no murmur, RS:Bilateral air entry +, mild Subcoastal recessions +, P/A :soft, no organomegaly, no abdominal distension, Cry/ tone /activity: good. There was difficulty in passing NG tube and Anal opening was absent (Figure 1). However, Meconium passage was observed through fistula tract opening near vestibule.

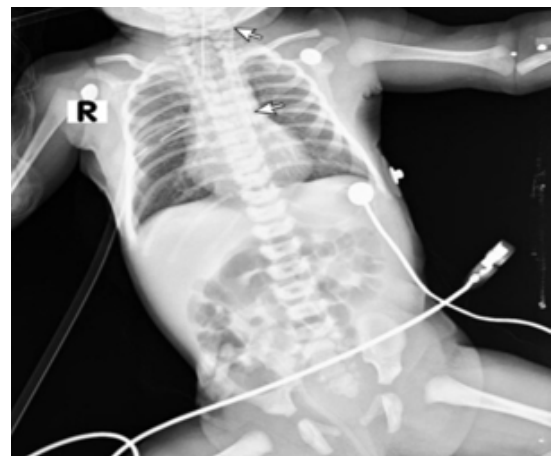


**Fig. 1:** Picture of neonate showing absent anal opening.

### 2.3. Investigations



**Fig. 2:** X-ray of neonate on day 1 of life showing coiling of OG tube and presence of gastric air bubble.



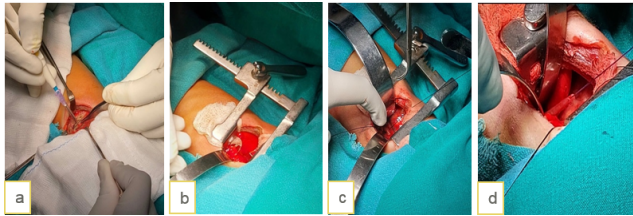
**Fig. 3:** Chest X-ray demonstrating an unusual course of the catheter (arrows) into the heart on the left side of the spine rather than the right side via the normal anatomical position of the SVC

Complete blood picture was normal, CRP was negative, Blood culture showed no growth after 48 hours of incubation, RFT, PT, aPTT, INR were normal. In suspicion of VACTERAL anomalies, 2D echo done was suggestive of Situs solitus Levocardia, PFO with left to right shunt, mild PAH and persistent left Superior venacava. Ultrasound Abdomen and KUB and Infantogram was normal. Genetics consultation was done. Chest x-rays showed coiling of OG tube of no.8 with presence of gastric air bubble (Figure 2) confirming the diagnosis.

## 2.4. Diagnosis

1. Tracheo oesophageal fistula with esophageal atresia
2. Imperforate anus with rectovestibular fistula.

The preoperative management was done with HHHFNC, IV fluids and suction within upper esophageal pouch. The patient was electively intubated, central line was placed through left Internal jugular vein (Figure 3). Intra-operative, it was identified as proximal atresia and distal Fistula. i.e. Type C TEF. Right thoracotomy, TEF repair and kissing type anastomoses of oesophagus was done. ICD placed and Loop sigmoid colostomy done for rectovestibular fistula.



**Fig. 4:** Intraoperative pictures. **a:** Dissection of 4<sup>th</sup> to 5<sup>th</sup> inter costal space; **b:** Rib spreader- Right lung exposure; **c:** Azygous vein dissection; **d:** Distal end of Esophageal after dissecting from fistula.

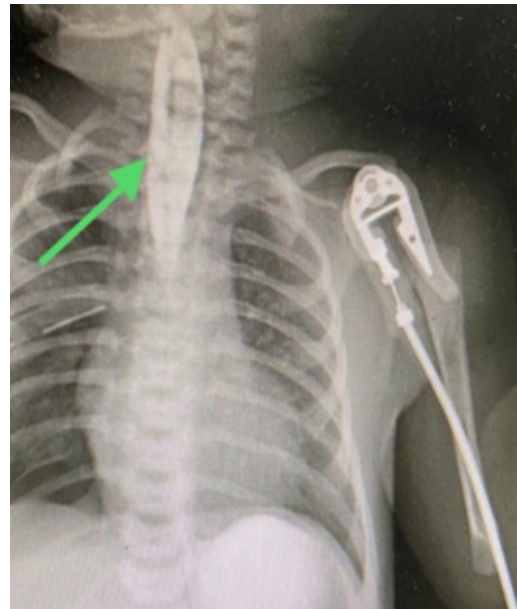Post operatively, respiratory support and inotropes were weaned off by day 3 POD. Esophagram done on 7th POD showed intact anastomosis with no leak (Figure 5). Infantogram was done to rule out vertebral and skeletal anomalies and was normal (Figure 6). Gastroesophageal reflux was managed by head-up positioning, lateral positioning, proton pump inhibitors. Oral feeds were started and was discharged on POD 20. At 1 month follow up, infant is doing well on oral feeds and proton pump inhibitors and colostomy care.

## 2.5. Differential diagnosis

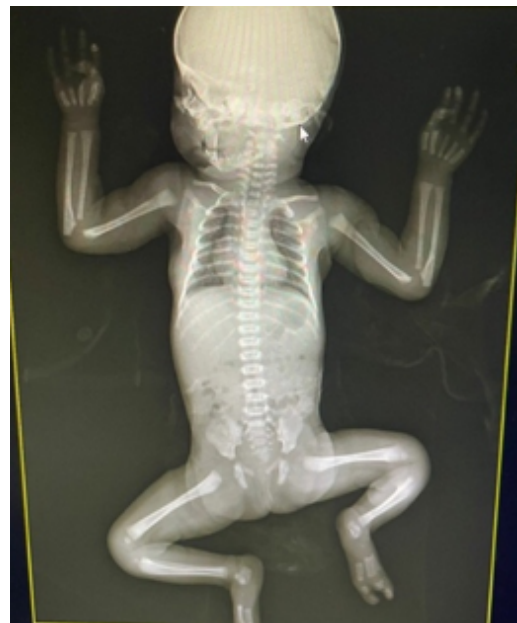Respiratory distress in Term neonate > Transient Tachypnea of Newborn, Meconium Aspiration Syndrome, Congenital Pneumonia, Sepsis, Congenital malformations –Congenital Diaphragmatic Hernia

## 3. Discussion

Quan and Smith first described VATER association in 1972<sup>2</sup>. 50 percent also have other birth defects. There is a wide spectrum of presentation as: isolated forms, a part of syndrome or a full and partial VACTERL and atypical VACTERL. Single umbilical artery is the most common atypical VACTERL. Type C configuration (proximal atresia with distal fistula) is the most common seen in 84% of cases.<sup>1</sup> Absence of major cardiac anomaly have favourable surgical outcomes. Postoperative complications are anastomotic leak, stricture, and recurrent fistula.



**Fig. 5:** Esophagram done in the neonate showing intact anastomosis with no leak.



**Fig. 6:** Infantogram of neonate was normal.

long-term outcomes :gastroesophageal reflux (GER) and esophagitis, vocal cord disorders, esophageal malignancy.

The present case was female neonate, presented on day 1 of life with signs and symptoms of TEF and associated congenital malformations. Amniotic fluid volume was normal and had atypical presentation with Single umbilical artery. The frequent complaints were increased work of breathing, tachypnoea, copious frothy mucus secretions in mouth, tachycardia. On examination, the neonate had

subcoastal retractions and absence of anal opening with fistula tract opening near vestibule. 2D echo showed pulmonary artery hypertension requiring inotrope support and central vein catheter passing through unusual course on chest X-ray which was confirmed on 2D echo as Persistent left Superior vena cava. No major congenital cardiac anomaly was found otherwise on 2D echo. Diagnosis is based on chest X-ray with rigid OG tube in situ which showed coiling of OG tube and underwent TEF repair surgery by end of Day 1 of life. Intraoperatively, identified as Type C TEF with proximal atresia and distal fistula. Loop colostomy was done for associated Anorectal malformation. Postoperative course was stable with no anastomotic leak observed on Esophagogram. Most common complication being GERD which was managed with head up positioning and proton pump inhibitors. The patient was continued post discharge on proton pump inhibitors for 6 months. During follow up visit at 1 month the baby was active and doing well.

From this we can infer that TEF can have atypical presentation with partial VACTERL presentation compared to study done by Simona La placca et al., in which out of 52 patients, 20 had isolated Esophageal atresia. Out of 32 remaining patients, 22 patients showed a recognizable pattern of multiple congenital anomalies (associations, syndromes or sequences), 10 with EA and other multiple malformations. The frequency of non-VACTERL-type anomalies varies in the literature: it has been reported a rate of 70% versus 57% reported by other studies<sup>7</sup> and much lower percentages by other authors.<sup>7</sup> Ten infants with EA and other multiple malformations did not meet the criteria for VACTERL diagnosis. Seven of them (70%) showed non-VACTERL-type anomalies with similar percentages compared with VACTERL population. The Single Umbilical Artery malformation was the most common non-VACTERL-type anomaly found in their study, with a percentage of 20% in VACTERL infants and 20% in infants with EA and other malformations. In our study, our case had TEF presenting with single umbilical artery.

As etiology of TEF is still unknown, diagnosis is based largely on phenotypical characters. As full VACTERL presentation may not be seen in all cases. So, to avoid missing of cases, suspicion of VACTERL should be considered in a wide presentation taking into consideration of partial VACTERL phenotype presentation and atypical presentations.

#### 4. Conclusion

TEF with Esophageal atresia can present with a wide spectrum of presentation from isolated TEF to atypical VACTERL. There is need for more detailed clinical definition and standardised approach for management and to start a proper short and long term follow-up of this complex congenital disease.

#### 5. Conflicts of Interest

All contributing authors declare no conflicts of interest.

#### 6. Source of Funding

None.

#### References

1. Available from: <https://rarediseases.org/for-patients-and-families/information-resources/info-clinical-trials-and-research-studies>.
2. Corsello G, Giuffrè M. Congenital malformations. *J Matern Fetal Neonatal Med.* 2012;25(S1):25–9. doi:10.3109/14767058.2012.664943.
3. Solomon BD. VACTERL/VATER association. *Orphanet J Rare Dis.* 2011;6:56. doi:10.1186/1750-1172-6-56.
4. Hall BD. Management of genetic syndromes. Suzanne B, Cassidy M, Allanson J, editors. Hoboken, New Jersey: Published by John Wiley & sons Inc; 2010. p. 871–8.
5. Temtamy SA, Miller JD. Extending the scope of the VATER association: definition of the VATER syndrome. *J Pediatr.* 1974;85(3):345–9. doi:10.1016/s0022-3476(74)80113-7.
6. Nora AH, Nora JJ. A syndrome of multiple congenital anomalies associated with teratogenic exposure. *Arch Environ Health.* 1975;30(1):17–21. doi:10.1080/00039896.1975.10666626.
7. Oral A, Caner I, Yigiter M, Kantarci M, Olgun H, Ceviz N, et al. Clinical characteristics of neonates with VACTERL association. *Pediatr Int.* 2012;54(3):361–4.

#### Author biography

**Gandra Abhinav**, Post Graduate  <https://orcid.org/0000-0002-6375-6089>

**Kota Vamshi**, Student

**S. Narasimha Rao**, HOD

**Cite this article:** Abhinav G, Vamshi K, Rao SN. An atypical case of tracheoesophageal fistula with esophageal atresia- Case report. *IP Int J Med Paediatr Oncol* 2022;8(4):172-175.