

Content available at: <https://www.ipinnovative.com/open-access-journals>

IP International Journal of Medical Paediatrics and Oncology

Journal homepage: <https://www.ijmpo.com/>

## Case Report

# Mucoepidermoid tumor of maxilla: A rare entity

Neha Sharma<sup>1</sup>, Deepti Sharma<sup>2,\*</sup>

<sup>1</sup>Dept. of Radiation Oncology, Lady Harding Medical College, New Delhi, India

<sup>2</sup>Dept of Radiation Oncology, Institute of Liver and Biliary Sciences., New Delhi, India



### ARTICLE INFO

#### Article history:

Received 03-04-2022

Accepted 25-05-2022

Available online 30-06-2022

#### Keywords:

Maxillectomy

Radiation therapy

Dentigerous cyst

Minor salivary gland tumor

Mucoepidermoid carcinoma maxilla

### ABSTRACT

Central mucoepidermoid carcinomas are rare neoplasms of the jaw, most commonly presenting in the mandible but in extremely rare cases they may present as a dentigerous cyst of the hard palate. Literature regarding their clinical features and treatment is scanty. In this case report of Mucoepidermoid tumor of the maxilla which presented as a dentigerous cyst, we have discussed the incidence, prevalence, clinical presentation, biological behavior and treatment options of central mucoepidermoid tumor.

This is an Open Access (OA) journal, and articles are distributed under the terms of the [Creative Commons Attribution-NonCommercial-ShareAlike 4.0 License](https://creativecommons.org/licenses/by-nc-sa/4.0/), which allows others to remix, tweak, and build upon the work non-commercially, as long as appropriate credit is given and the new creations are licensed under the identical terms.

For reprints contact: [reprint@ipinnovative.com](mailto:reprint@ipinnovative.com)

## 1. Introduction

Mucoepidermoid carcinoma is the most common type of malignant salivary gland tumor. Its most common site of origin is parotid gland followed by other minor salivary glands in the palate. It usually occurs between third to fifth decade of life with female predilection.<sup>1,2</sup> MEC of maxilla is very rare entity. In this present case report we will discuss case of MEC of maxilla which initially presented as dentiginous cyst.

## 2. Case Report

A 35 years old female presented with complaints of swelling of the palate and discharge from right nasal cavity off and on since Nov 2018. There was no significant family history and use of tobacco. With these complaints, the patient was evaluated at the Department of Dental Sciences. On examination, the face was normal. The submental and submandibular lymph nodes were not palpable or tender. On intraoral examination, swelling was smooth, firm and tender

on palpation involving the anterior region of maxilla from the right lateral incisor to the right first premolar with the intact overlying mucosa. The right canine tooth was absent. Her CT scan Paranasal sinus (04.12.18) showed destruction of the right upper alveolar margin with lifting of floor of right maxillary antrum. Tooth seen embedded in soft tissue mass of 40 x 24mm involving hard palate. The findings were suggestive of keratocystic odontogenic tumor. [Figures 1 and 2]

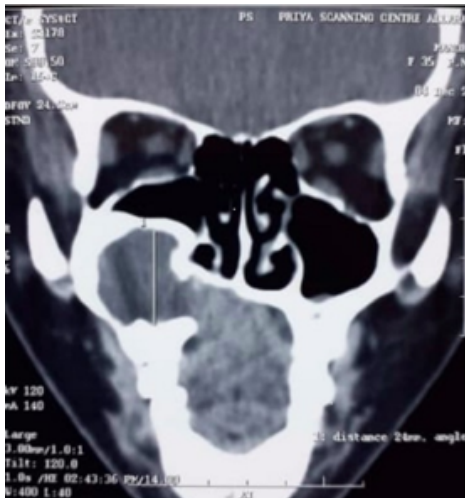She underwent Curettage of cystic lesion, teeth extraction and peripheral ostectomy in March 2019, HPE of which was s/o Low Grade Mucoepidermoid tumor.

She presented in Jan 2020 with swelling of the right side palatal region. CT scan findings suggested that the lesion was extensive, osteolytic with its epicenter within the maxilla. This led us to give a radiological diagnosis of primary intraosseous carcinoma of maxilla [Figure 3].

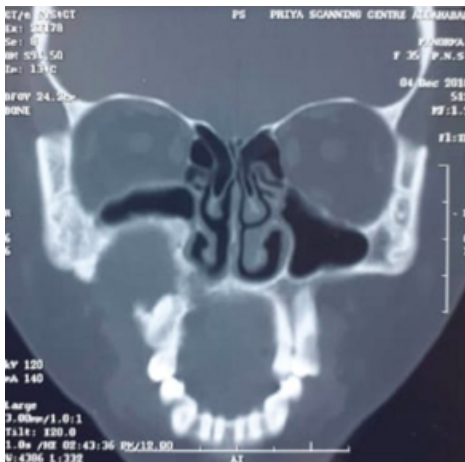Patient then underwent Right partial maxillectomy as a part of completion surgery in Feb 2020. Final HPE: Tumor size- 2.2 x 1.8 x 0.8 cms. DOI- 8 mm, Positive medial margin and close posterior margin (0.1 cm). Mucoepidermoid Ca, High grade- rpT4aNxMx.

\* Corresponding author.

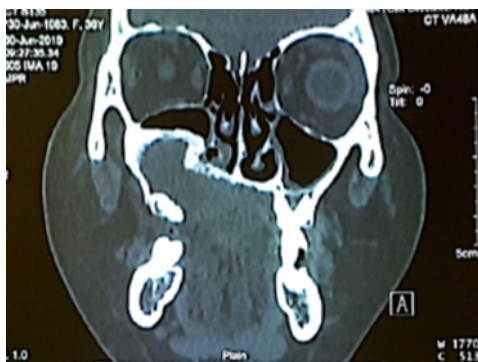E-mail address: [drdeeptisharma16@gmail.com](mailto:drdeeptisharma16@gmail.com) (D. Sharma).



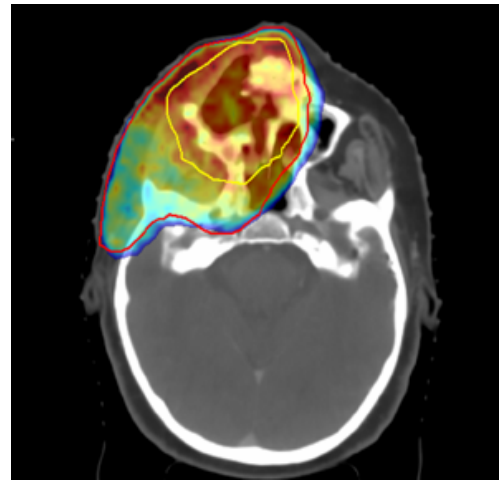
**Fig. 1:** CT scan (coronal section) showing destruction of the right upper alveolar margin with lifting of floor of right maxillary antrum



**Fig. 2:** CT scan Bone window (coronal section) showing destruction of the right upper alveolar margin with lifting of floor of right maxillary antrum



**Fig. 3:** CT scan showing radiolucency in right maxillary bone



**Fig. 4:** Radiation therapy planning: colour wash of 60Gy to PTV 60 Gy in Red and PTV 66Gy in yellow

In view of high grade tumor and positive margins, the patient received radiation therapy to the tumor bed in the dose 66 Gy in 33 fractions. The patient has been kept on regular follow up and is doing well.

### 3. Discussion

Wide range of jaw lesions can arise from odontogenic epithelium surrounding an impacted teeth which can be differentiated from cysts to neoplasms including adenomatoid odontogenic tumor, ameloblastoma, Mucoepidermoid carcinoma, and squamous cell carcinoma has been reported.<sup>2</sup>

The most common malignancy of the major and minor salivary glands is Mucoepidermoid carcinoma (MEC), accounting for less than 3% of all head and neck tumors. It comprises 34% of all salivary gland malignancies.<sup>3</sup> They occur in all age groups ranging from 15 to 86yrs, but are most common in middle age (mean age 49 years) with predilection for females as compared to males.<sup>4</sup> These most commonly arise from major salivary gland (89.6%), submandibular gland (8.4%), and sublingual gland (0.4%).<sup>1</sup> These also arise from minor salivary glands in palate being the most common location, followed by the glands in retromolar trigone, floor of the mouth, buccal mucosa, lip, tongue, and anywhere in the proximal aerodigestive tract, the lacrimal glands and even in the bronchi.<sup>4</sup> Central MEC (CMEC) is a rare primary intraosseous bony lesion with an incidence of 2%-4.3% of all MECs reported, which occurs almost always in the mandible and MEC of the maxilla presenting as dentigerous cyst is extremely rare.<sup>5</sup>

Clinical features of MEC of the hard palate are usually a persistent swelling which is soft in consistency, slow-growing and painless. However, if the lesion has a secondary infection then it can present with pain and pus discharge. Tooth mobility, resorption of the root or underlying bone,

ulceration, numbness of adjacent teeth, and indurated mass are the symptoms of advanced disease. Delayed diagnosis results in extensive proliferation, and can cause perforation of the hard palate and invasion into maxillary antrum or nasal cavity.<sup>6</sup>

A staging system for CMEC was introduced by Brookstone and Huvos that includes Stage I: Intact cortical plate without expansion, Stage II: Intact cortical plate with bony expansion, and Stage III: Any cortical perforation or breakdown of the overlying periosteum or nodal spread.<sup>7</sup> In our patient, there was expansion in the buccal cortical plate; thus, it can be considered as Stage II.

Histological grading of MEC can correlate to its clinical behaviour. They are classified as low-, intermediate, and high grade types. A macroscopically small and partially encapsulated mass and microscopically characterized by the presence of more mucous-producing cells is denoted a Low grade MEC. The intermediate-grade MEC has predominantly solid architecture with more intermediate cells. The high-grade tumor has solid islands of squamous and intermediate cells and also exhibits considerable pleomorphism and mitotic activity. Mucous cells are infrequent.<sup>8</sup> In the present case, a histopathological diagnosis confirmed the lesion to be high-grade MEC.

Treatment of MEC depends on its grade, spread and aggressiveness of the tumor. When the tumor is confined to the palatal mucosa with intact periosteum, wide excision of lesion along with underlying mucoperiosteum is advised. If it infiltrates the periosteum with erosion of underlying bone, excision of lesion along with the underlying bone is indicated. If the lesion is restricted to the alveolar region, alveolectomy is performed. This consists of removal of the affected alveolus and a limited portion of the maxilla.<sup>9</sup> which was performed in our patient. After 5 years of follow up if no tumor recurrence occurs then reconstruction using bone and soft tissue grafts can be performed.<sup>10</sup> Our patient underwent right partial maxillectomy and also received radiation therapy to the tumor bed owing to high grade and positive margins. Although MEC is viewed as a radioresistant tumor, studies have suggested that postoperative radiotherapy improves local control and decreases local failure.<sup>11</sup>

Surgery is the mainstay of treatment in these cases. However, the rehabilitation of the patients is a matter of concern since the patient undergoes drastic facial surgery.

#### 4. Conclusion

Intraosseous MEC are extremely rare tumors but should be included in the differential diagnosis of proliferative and osteolytic lesions of the palatal bones even when the clinical or radiological findings do not suggest malignancy. Early intervention and systematic follow-up ensure a favorable

prognosis in these patients.

#### 5. Conflict of Interest

The authors declare no relevant conflicts of interest.

#### 6. Source of Funding

None.

#### References

1. Simon D, Somanathan T, Ramdas K, Pandey M. Central Mucoepidermoid carcinoma of mandible - A case report and review of the literature. *World J Surg Oncol*. 2003;1:1. doi:10.1186/1477-7819-1-1.
2. Kalburge J, Latti B, Kalburge V, Kulkarni M. Neoplasms associated with dentigerous cyst: An insight into pathogenesis and clinicopathologic features. *Arch Med Health Sci*. 2015;3(2):309–13. doi:10.4103/2321-4848.171936.
3. Spiro RH. Salivary neoplasms: overview of a 35-year experience with 2,807 patients. *Head Neck Surg*. 1986;8(3):177–84. doi:10.1002/hed.2890080309.
4. Handra-Luca A, Hang JF. Mucoepidermoid carcinoma. PathologyOutlines.com; 2022. Available from: <https://www.pathologyoutlines.com/topic/salivaryglandsMEC.html>.
5. Khalesi S, Razavi S, Yahyaabadi R. A case of central mucoepidermoid carcinoma associated with dentigerous cyst. *Dent Res J*. 2017;14(6):423–6. doi:10.4103/1735-3327.218564.
6. Prerana T, Gadipelly S, Batchu PK, Kothia P. Mucoepidermoid Carcinoma of Palate - A Case Report and Review of Literature. *Indian J Dent Adv*. 2018;10(4).
7. Brookstone MS, Huvos AG. Central salivary gland tumors of the maxilla and mandible: A clinicopathologic study of 11 cases with an analysis of the literature. *J Oral Maxillofac Surg*. 1992;50(3):229–36. doi:10.1016/0278-2391(92)90317-s.
8. Seethala RR. An update on grading of salivary gland carcinomas. *Head Neck Pathol*. 2009;3(1):69–77. doi:10.1007/s12105-009-0102-9.
9. Moore BA, Burkey BB, Netterville JL, Butcher RB, Amedee RG. Surgical management of minor salivary gland neoplasms of the palate. *Ochsner J*. 2008;8(4):172–80.
10. Hatamleh M, Haylock C, Watson J, Watts D. Maxillofacial prosthetic rehabilitation in the UK: a survey of maxillofacial prosthetists' and technologists' attitudes and opinions. *Int J Oral Maxillofac Surg*. 2010;39(12):1186–92. doi:10.1016/j.ijom.2010.08.002.
11. Ozawa H, Tomita T, Sakamoto K, Tagawa T, Fujii R, Kanzaki S, et al. Mucoepidermoid Carcinoma of the Head and Neck: Clinical Analysis of 43 Patients. *Japanese J Clin Oncol*. 2008;38(6):414–8. doi:10.1093/jjco/hyn045.

#### Author biography

**Neha Sharma**, Assistant Professor  <https://orcid.org/0000-0002-8781-3172>

**Deepthi Sharma**, Associate Professor  <https://orcid.org/0000-0002-9911-3384>

**Cite this article:** Sharma N, Sharma D. Mucoepidermoid tumor of maxilla: A rare entity. *IP Int J Med Paediatr Oncol* 2022;8(2):95-97.