

Content available at: <https://www.ipinnovative.com/open-access-journals>

IP International Journal of Medical Paediatrics and Oncology

Journal homepage: <https://www.ijmpo.com/>

## Case Report

# Isolated gallbladder perforation in paediatric blunt abdominal injury: A case report and review of literature

Arka Banerjee<sup>1</sup>, Shasanka S Panda<sup>1</sup>, Sujoy Neogi<sup>1,\*</sup>, Simmi K Ratan<sup>1</sup>

<sup>1</sup>Dept. of Pediatric Surgery, Maulana Azad Medical College, New Delhi, India



## ARTICLE INFO

### Article history:

Received 26-04-2021

Accepted 16-06-2021

Available online 03-08-2021

### Keywords:

Gallbladder  
Perforation  
Laceration  
Abdominal  
Trauma  
Injury

## ABSTRACT

Gallbladder injury in blunt abdominal trauma is rare, around 2% of all abdominal traumas. Vague symptoms and inconclusive imaging make it an elusive diagnosis, more so in children. Only 30 paediatric cases have been reported worldwide till date. We report a case of a 7yrs old boy presenting 2 weeks after a road accident with a gallbladder rupture which was eventually discovered on a diagnostic laparoscopy. This is the second such case being reported from India. The injury is most often identified at exploration and although cholecystectomy is the preferred treatment, there are occasions when the gallbladder may be left in situ. The classification system of Losanoff and Kjossev has merit in guiding treatment. The various presentations, mechanisms and modes of injury have been highlighted along with the clinical and imaging findings. Despite the developments in modern radiology, identifying gallbladder perforation has always been difficult because of the rarity of the condition. In a child with blunt abdominal trauma and intra-abdominal free fluid without any solid organ injury, a diagnostic peritoneal tap may be helpful. Based on the current evidence, we advocate a low threshold for performing a diagnostic laparoscopy in all such cases.

© This is an open access article distributed under the terms of the Creative Commons Attribution License (<https://creativecommons.org/licenses/by/4.0/>) which permits unrestricted use, distribution, and reproduction in any medium, provided the original author and source are credited.

## 1. Introduction

Perforation of the gallbladder due to blunt abdominal trauma is rare, seen in around 1.9-2.1% of all cases.<sup>1</sup> It is usually associated with concomitant visceral injuries in 90% of cases,<sup>2,3</sup> most commonly, hepatic (83-91%). It presents late, with non-specific symptoms and inconclusive results on imaging; hence, is often diagnosed at exploration.<sup>4,5</sup> It presents additional challenges in children as the history is difficult to obtain, anatomy is different and physical signs are unreliable because of compensating physiology.<sup>3</sup>

Isolated gallbladder perforation is extremely rare after blunt abdominal trauma.<sup>2-6</sup> In the paediatric population, only 30 cases have been reported worldwide till date. This is the second such case being reported from India.

## 2. Case Report

A 7-year-old boy with unremarkable previous medical history was referred to our centre from a peripheral hospital for management of progressive abdominal distension associated with fever and vomiting for the past 10 days. Symptoms started 2 weeks prior to admission, following an accident, in which he got run over by a motorcycle. He suffered no external injuries at that time and had mild abdominal discomfort. There was progressive abdominal distension and intermittent pain. Around 10 days prior to admission, the symptoms worsened with severe abdominal pain, aggravated by meals, along with post-prandial vomiting with food debris in vomitus.

On admission, he had a heart rate of 110/min; BP: 90/70 mm Hg, RR: 28/minute and was afebrile. The patient was pale but there was no icterus. He had significant abdominal distension. Palpation revealed diffuse tenderness and guarding of the abdomen. Blood investigations were grossly normal except for mild elevation in the total

\* Corresponding author.

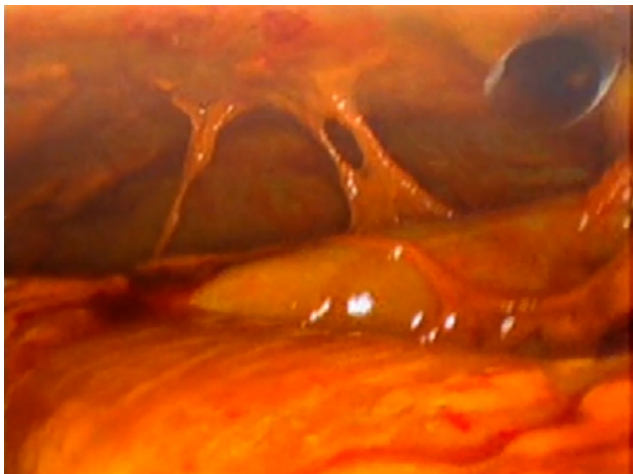
E-mail address: [drsujoneogi@yahoo.com](mailto:drsujoneogi@yahoo.com) (S. Neogi).

Bilirubin (1.6 mg/dl). Plain abdominal X-ray showed a pushed-up diaphragm and diffuse haziness; there was no free gas under diaphragm. USG revealed gross ascites with internal echoes without any solid organ injury. CECT of the abdomen revealed gross ascites with no evidence of pneumoperitoneum and a fracture of the iliac bone. A diagnostic peritoneal tap was done and frank bilious fluid aspirated.

An intraperitoneal drain was inserted to alleviate the massive distension and respiratory distress. Around 1 litre of bilious effluent came in the drain immediately on insertion and the child was taken up for urgent diagnostic laparoscopy. Around 300ml bilious fluid was found in the abdomen with multiple enteric adhesions and abdominal wall adhesions to the small intestines. [Figure 1] A loop of jejunum was found adhered to the undersurface of liver and the gallbladder. On careful dissection, we discovered a laceration on the fundus of the gallbladder measuring about 1.5 cm in length. [Figure 2] Extra-hepatic bile ducts were intact as well as the duodenum, spleen, kidneys, stomach, bladder, colon and small intestine. We performed adhesiolysis, peritoneal lavage, retrograde cholecystectomy and drainage of the peritoneal cavity via a pelvic drain and another in the Morrison's pouch. Broad spectrum antibiotics were given post-operatively. The post-operative phase was uneventful. The patient was orally allowed from the 1<sup>st</sup> post-operative day and was eventually discharged on the 4<sup>th</sup> day after removal of both the drains.

Histological examination showed chronic (post-traumatic) haemorrhagic cholecystitis.

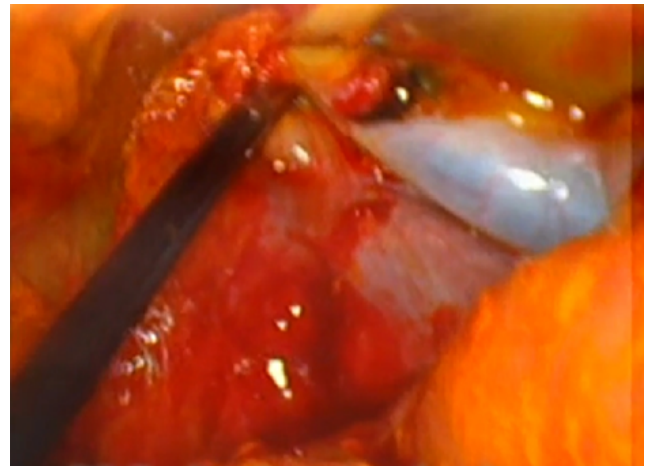
At 6 months post-op, the child is symptom-free.



**Fig. 1:** Initial view on laparoscopy showing bilious contamination and adhesions with anterior abdominal wall

### 3. Review of Literature

The first known report of a traumatic rupture of gall bladder in an adult patient is from the pathology museum at Guy's



**Fig. 2:** Gall bladder perforation

Hospital, London and dates back to 1388. In 1785, Skeete reported the first paediatric patient with isolated gallbladder perforation.<sup>7</sup>

In 1898, Thomas reported the first successful cholecystectomy done for an isolated gallbladder trauma in a 14 yrs. Old boy. Czerny, in 1899, did the first cholecystorrhaphy for a child who was run over by a wagon and had two lacerations of the gallbladder without any other visceral injury.<sup>8</sup>

Till date, around 280 cases of isolated gallbladder injury from blunt abdominal trauma have been reported worldwide of which only 23 have been in children. The only other report from India was of a 12 yrs. old boy who suffered a gallbladder perforation reportedly from a trivial abdominal trauma while trying to bend over a water tank.<sup>9</sup>

#### 3.1. Classification

Niemeier was the first one to recognize and classify the condition in 1934<sup>10</sup> which was later classified by Smith and Hastings<sup>11</sup> and further modified by Penn in 1962.<sup>1</sup> The latest classification system proposed by Losanoff and Kjossev in 1999<sup>12</sup> is based on Smith and Hastings' subdivisions. Table 1

#### 3.2. Mechanism of injury

Traumatic injury to the gallbladder may be penetrating or blunt. Penetrating trauma, most commonly projectile and knife injuries, are rare in the paediatric population. Most cases are due to road traffic accidents as was the case in our patient, or after a direct blow on the abdomen from abdominal punches, kicks and falls.<sup>2,4</sup>

The low incidence of the condition is because of the gallbladder lying on the undersurface of the liver and hence, having bony protection from the ribs and also because of the liver acting as a shock absorbent.<sup>13,14</sup> The thin-

**Table 1:** Losanoff and Kjossev's classification of Gallbladder injuries

1	1A	Contusion + Intramural hematoma	Conservative/Cholecystectomy
	1B	Contusion + Intramural hematoma + Necrosis with eventual perforation	Cholecystectomy
2		Wall rupture at injury	Cholecystectomy
3	3A	Partial avulsion	Conservative/Cholecystopexy/Cholecystectomy
	3B	Complete avulsion with intact HDL	Cholecystectomy
	3C	HDL detached; Liver bed intact	Cholecystectomy
4	3D	Total avulsion/Traumatic cholecystectomy	Hemostasis/Cystic duct clipping
	4A	Traumatic cholecystitis	Cholecystectomy with evacuation of hemobilia
5	4B	Acalculous cholecystitis complicating trauma	Conservative/Cholecystectomy
		Mucosal tear (GB wall intact)	Cholecystorrhaphy/Cholecystectomy

walled and distended gallbladder is most susceptible to the risk of perforation when traumatized. Anything dilating the gallbladder like a distal obstruction or a recent meal increases the likelihood of perforation.<sup>15</sup>

### 3.3. Type of injury

Gall bladder injuries can be in the form of a contusion, laceration, perforation or avulsion.

Contusion is classically described as the presence of intramural hematoma, which may be self-limiting.

Lacerations or perforations are defined as transmural injuries with or without a mucosal injury and hence, may or may not cause a biliary peritoneal leak.

Avulsions are thought to occur when deceleration forces are applied in the presence of a distended or full gallbladder where the gall-bladder tissue and fluid behave differently during the deceleration motion causing the avulsion. It can be subdivided as partial avulsion (partial separation of the gallbladder from the liver bed) or complete avulsion (complete removal of the gallbladder from the liver bed with an intact attachment of the cystic duct and artery) or very rarely, total avulsion, i.e., the removal of all anatomic attachments of the gallbladder, also known as 'Traumatic cholecystectomy'.<sup>16,17</sup> There have been only 11 cases of traumatic cholecystectomy or total gallbladder avulsion reported after blunt abdominal injury, out of which 3 were reported in children.<sup>18–20</sup>

### 3.4. Clinical presentation

There is no gender or age predilection,<sup>21</sup> though only 4 out of 30 children reported were girls.

Unlike injuries to viscera such as the liver or spleen, where the onset of acute symptoms and signs is rapid, in the majority of cases with a ruptured gall-bladder, the diagnosis of an acute abdominal condition has been delayed for 36 hours or more after the injury.<sup>22</sup>

Some patients may present with peritonitis from the initial trauma caused by a persistent biliary leak. In most cases, the initial symptom is mild abdominal discomfort

followed by a period of remission which is then likely followed by acutely worsening biliary peritonitis. The length of this remission period varies significantly which can be explained by the fact that sterile bile causes less peritoneal irritation and hence, only minimal symptoms and signs of peritoneal irritation are present for the first 24-48 hours.<sup>23</sup>

### 3.5. Diagnosis

The diagnostic challenge in a case of isolated gallbladder perforation is the interpretation of the investigations. The patient often has a distended abdomen. Vomit or nasogastric aspirate may not contain bile, suggesting a nonmechanical obstruction, a lack of bile in the duodenum or both. In the scenario of abdominal trauma presenting with abdominal distension without any obvious detectable visceral injury, a diagnosis of ileus is generally made, delaying the diagnosis of a gallbladder perforation.

#### 3.5.1. Imaging

A plain abdominal erect X-ray rarely reveals free air in a case of isolated gallbladder perforation and thus its only value is to exclude an associated hollow viscus injury.<sup>24</sup>

Ultrasonography allows imaging of defects in the gallbladder wall.<sup>3</sup> Echogenic fluid within the gallbladder may lead to a suspicion of bleeding into the lumen.<sup>25</sup> It may also be possible to demonstrate a gallbladder injury directly using Doppler flow measurement of bile through the perforation.<sup>26</sup>

A computed tomography (CT) scan can identify a rupture of the gallbladder. The gallbladder contour may be irregular or a hematoma may be present in the gallbladder lumen. However, any overlying liver injury may overshadow this. Pericholecystic fluid is most often identified, but it is a nonspecific finding.<sup>27</sup>

The use of hepatobiliary scintigraphy for the detection of traumatic gallbladder injury has been described in a single case report of an infant with jaundice and a normal liver after blunt abdominal trauma who was subsequently operated and found to have a gallbladder perforation.<sup>5</sup>

MRI can also be used as an evaluative tool in assessing the nature of intraperitoneal fluids though it gives little additional diagnostic benefit to CT in terms of tissue imaging. It is possible to make conclusions as to the nature of the fluid as a result of the changing T1 and T2 signal.<sup>28</sup>

### 3.6. Management

Any patient who is unstable or demonstrating signs of peritonitis requires immediate laparotomy. However, a child with an isolated gallbladder injury may not exhibit a classical peritonitic abdomen. In a typical scenario of blunt abdominal trauma, the presence of intraperitoneal free fluid on computed tomographic (CT) scan along with the absence of a detectable solid organ injury or bowel perforation should prompt surgeons to consider a gallbladder perforation. Though obsolete in today's scenario because of an increasing reliance upon radiology and use of diagnostic laparoscopy, a diagnostic peritoneal tap can be done in cases with abdominal distension due to ascites and no discernible cause. The finding of a bile-stained fluid on diagnostic paracentesis is suggestive, but can also occur when the duodenum has been injured. One has to keep in mind that a negative paracentesis does not exclude a gallbladder injury.

Still, the most common way to find a gallbladder perforation is during a laparotomy, especially when it usually occurs in conjunction with other intra-abdominal injuries that have been the main indication of the need to perform surgery. In isolation, making the diagnosis is more difficult because the subtle clinical presentation of an isolated gallbladder perforation seldom mandates a laparotomy.

But, in general, the morbidity associated with a negative laparotomy is supposed to be less than any missed underlying injury. Hence, a diagnostic laparoscopy should be done, especially in cases where abdominal distension is not marked enough to warrant a formal laparotomy.

### 3.7. Surgery

The treatment of a patient with isolated gallbladder injury depends on the severity of the injury. The classification system of Losanoff and Kjossev has merit in guiding treatment here.

An argument exists for performing a cholecystopexy in the case of partial avulsion to minimize any progression, but there is very little evidence to support this.<sup>5</sup> There have been complications from conservative management, most notably fistula formation, especially when non-absorbable sutures have been used to suture the defect in the gallbladder.<sup>29</sup>

A simple contusion or partial avulsion may be managed by a simple suture (cholecystorrhaphy). It is usually satisfactory in cases where there is a small wound in an otherwise healthy gall-bladder.<sup>5,11</sup> Injuries of the gall-

bladder heal fairly quickly. However, there is a significant risk of initiating cholecystitis, re-rupture and gallbladder wall necrosis. A subset of patients, particularly those who are immunocompromised or have systemic disease, may present later with "traumatic cholecystitis" or a late perforation.<sup>1,30</sup>

Cholecystostomy has been performed in compromised patients to temporize and facilitate drainage.<sup>11,31</sup> The drainage-tube may be inserted through the laceration in the gallbladder wall, if this is suitably situated, or the laceration may be repaired and a separate drainage opening made.

These conservative measures are particularly indicated where there are other associated serious injuries, as they are simpler and quicker procedures than cholecystectomy.

Cholecystectomy is preferred in cases of gallbladder perforation<sup>1,5,32</sup> and in patients with a complete or total avulsion of the gallbladder. The majority of patients who have early operative intervention make full and uneventful recoveries.<sup>5,13,33,34</sup> In the rare scenario of an underlying gallbladder pathology or cholelithiasis, the gallbladder should always be removed because the risk of later complication with conservative approaches increases.<sup>1,5</sup>

Whatever form of definitive treatment is adopted, all free blood and bile should be removed and the hepato-renal pouch should be drained. Any associated visceral damage should be searched for and, if found, repaired.

### 3.8. Outcome

Early analyses claimed mortality rates of up to 40% but these estimates have decreased significantly over the years with modern improvements in the treatment of shock and infection. Not a single case of mortality following isolated traumatic gall bladder rupture has been reported since 1901. It can be inferred here that the reported mortality is most likely attributable to the associated injuries and not the gallbladder rupture per se.

## 4. Conclusion

Gallbladder trauma occurs in 1.9-2.1% of all abdominal trauma and is frequently associated with other visceral injuries and is rarely seen in isolation. In children, it is a challenging diagnosis as the presentation is vague. Furthermore, a gallbladder injury may also have a delayed presentation and it is advisable to exercise caution in cases of blunt abdominal trauma with intra-abdominal free fluid, in the absence of solid organ injury. CT imaging is potentially diagnostic but because of the rarity and subtlety of the diagnostic signs, it is easily missed by the interpreting radiologist. Careful serial observation and imaging is only advised in cases where the volume of fluid is negligible and the energy of trauma is low. Surgery is advised in all other cases. As such, the injury is most often identified intra-operatively and not all cases mandate cholecystectomy. We

advocate diagnostic laparoscopy to confirm the findings and proceed accordingly. Provided gallbladder injuries are recognized early and there are no serious associated visceral injuries, these patients have an excellent prognosis.

## 5. Conflict of Interest

The authors declare that there are no conflicts of interest in this paper.

## 6. Source of Funding

None.

## References

- Penn I. Injuries of the gall-bladder. *Br J Surg.* 2005;49(218):636–41. doi:10.1002/bjs.18004921816.
- Soderstrom C, Maekawa K, Dupriest RW, Cowley RA. Gallbladder Injuries Resulting from Blunt Abdominal Trauma. *Ann Surg.* 1981;193(1):60–6. doi:10.1097/00000658-198101000-00010.
- Jaggard MKJ, Johal N, Haddad M, Choudhry M. Isolated gallbladder perforation following blunt abdominal trauma in a six-year-old child. *Ann R Coll Surg Engl.* 2011;93(5):e29–e31. doi:10.1308/147870811x580479.
- Wiener I, Watson LC, Wolma FJ. Perforation of the gallbladder due to blunt abdominal trauma. *Arch Surg.* 1982;117:805–7.
- Sharma O. Blunt gallbladder injuries: presentation of twenty-two cases with review of the literature. *J Trauma Acute Care Surg.* 1995;39(3):576–80.
- Bainbridge J, Shaaban H, Kenefick N, Armstrong CP. Delayed presentation of an isolated gallbladder rupture following blunt abdominal trauma: a case report. *J Med Case Rep.* 2007;1(1):52. doi:10.1186/1752-1947-1-52.
- Ricketts BM. Rupture of the gallbladder (spontaneous and traumatic, with and without operation) an historical review of 273 cases. *St Louis Med Rev.* 1905;(51):108–21.
- Lewerenz IS. Yber die subcutanen rupturen der gallenwege traumatischen ursprungs nebst einem casuistischen beitrage. *Archf Klin Chir Berl.* 1903;71:111–46.
- Balmiki P, Ionare R, Apte A, Sr NT. Isolated gallbladder perforation after trivial abdominal trauma in a child : a case report and review of the literature. *IOSR J Dent Med Sci.* 2014;13(9):44–51.
- Niemeier O. Acute free perforation of the gall-bladder. *Ann Surg.* 1934;99(6):922–44.
- Smith SW, Hastings TN. Traumatic rupture of the gallbladder. *Ann Surg.* 1954;139(4):517–20. doi:10.1097/00000658-195404000-00019.
- Losanoff JE, Kjossev KT. Complete traumatic avulsion of the gallbladder. *Injury.* 1999;30(5):365–8. doi:10.1016/s0020-1383(99)00072-8.
- Schechter D. Solitary wounding of gallbladder from the blunt abdominal trauma. *NY State J Med.* 1969;(69):2895–901.
- Kwan BY, Plantinga P. Isolated traumatic rupture of the gallbladder. *Radiol Case Rep.* 2015;10(1):1029. doi:10.2484/rcr.v10i1.1029.
- Pavlidis TE, Lalountas MA, Psarras K, Symeonidis NG, Tsitlakidis A, Pavlidis ET. Isolated complete avulsion of the gallbladder (near traumatic cholecystectomy): a case report and review of the literature. *J Med Case Rep.* 2011;5(1):392. doi:10.1186/1752-1947-5-392.
- Ball CG, Dixon E, Kirkpatrick AW, Sutherland FR, Laupland KB, Feliciano DV, et al. A decade of experience with injuries to the gallbladder. *J Trauma Manag Outcomes.* 2010;4(1):3. doi:10.1186/1752-2897-4-3.
- A MW. CT diagnosis of traumatic gallbladder injury. *Am J Roentgenol.* 2005;185(6):1573–4.
- Robertson H. The injured abdomen: a consideration of visceral injuries due to trauma where the abdominal wall has not been perforated. *Am J Surg.* 1931;14(2):395–418.
- Norgore M. Traumatic rupture of the gallbladder: case reports and notes on choleperitoneum. *Ann Surg.* 1946;123(1):127–34.
- Behdad A. Torsion and gangrene of the gallbladder in a child. *Med J Islam Repub Iran.* 1998;12(2):191–2.
- Birn J, Jung M, Dearing M. Isolated gallbladder injury in a case of blunt abdominal trauma. *J Radiol Case Rep.* 2012;6(4):25–30.
- Manlove CH, Quattlebaum FW, Ambrus L. Non-penetrating trauma to the biliary tract. *Am J Surg.* 1959;97(1):113–6. doi:10.1016/0002-9610(59)90286-7.
- Cope Z. Extravasation of bile. *Br J Surg.* 2005;13(49):120–9. doi:10.1002/bjs.1800134913.
- Sengstaken R. Traumatic rupture of the gallbladder. *Ann Surg.* 1944;119:959.
- Kauzlaric D, Barneir E. Sonography of intraluminal gallbladder hematoma. *J Clin Ultrasound.* 1985;13(4):291–4. doi:10.1002/jcu.1870130412.
- Konno K, Ishida H, Sato M, Watanabe S, Obara K, Andoh H, et al. Gallbladder perforation: color Doppler findings. *Abdom Imaging.* 2002;27(1):47–50. doi:10.1007/s00261-001-0048-1.
- Estevão-Costa J, Soares-Oliveira M, Lopes JM, Carvalho JL. Idiopathic Perforation of the Gallbladder: A Novel Differential Diagnosis of Acute Abdomen. *J Pediatr Gastroenterol Nutr.* 2002;35(1):88–9. doi:10.1097/00005176-200207000-00019.
- Baumgartner FJ, Barnett MJ, Velez M, Chiu LC. Traumatic disruption of the gallbladder evaluated by computerized tomography and magnetic resonance imaging. *Br J Surg.* 2005;75(4):386–7. doi:10.1002/bjs.1800750432.
- Grimes O, Steinbach H. Traumatic cholecystocutaneous fistula. *AMA Arch Surg.* 1955;71(1):68–70.
- Fawaz F, Kim S. A case of traumatic cholecystitis. *W V Med J.* 1985;81(2):32.
- Fortier L. Subcutaneous traumatic rupture of the gallbladder. *New Orleans Med Surg J.* 1915;67:448–9.
- Carrillo EH, Lottenberg L, Saridakis A. Blunt Traumatic Injury of the Gallbladder. *J Trauma Acute Care Surg.* 2004;57(2):408–9. doi:10.1097/01.ta.0000037286.60472.b7.
- Johnson W, Harris P. Isolated gallbladder injury secondary to blunt abdominal trauma : case report. *ANZ J Surg.* 1982;52(5):495–6. doi:10.1111/j.1445-2197.1982.tb06037.x.
- Laffey DA, Hay DJ. Isolated perforation of the gall bladder following blunt abdominal trauma. *Postgrad Med J.* 1979;55(641):212–4. doi:10.1136/pgmj.55.641.212.

## Author biography

**Arka Banerjee**, Senior Resident

**Shasanka S Panda**, Associate Professor

**Sujoy Neogi**, Associate Professor  <https://orcid.org/0000-0001-6919-5457>

**Simmi K Ratan**, Professor

**Cite this article:** Banerjee A, Panda SS, Neogi S, Ratan SK. Isolated gallbladder perforation in paediatric blunt abdominal injury: A case report and review of literature. *IP Int J Med Paediatr Oncol* 2021;7(2):103-107.