

Content available at: <https://www.ipinnovative.com/open-access-journals>

IP International Journal of Medical Paediatrics and Oncology

Journal homepage: <https://www.ipinnovative.com/journals/IJMPO>

## Case Report

# Jejuno-jejunal intussusception in a neonate without any lead point: A rare case report

Simmi K Ratan<sup>1</sup>, Ashish Kumar<sup>1</sup>, Shashank Shekhar Panda<sup>1</sup>, Sujoy Neogi<sup>1,\*</sup>

<sup>1</sup>Dept. of Pediatric Surgery, Maulana Azad Medical College, New Delhi, India



### ARTICLE INFO

#### Article history:

Received 27-07-2020

Accepted 31-10-2020

Available online 09-01-2021

#### Keywords:

Intussusception

Jejunojejunal

Lead point

Neonate

Gangrene

### ABSTRACT

Neonatal intussusception is rare entity. We report this very rare case of a term male newborn, with acute jejunojejunal intussusception without any lead point. He presented with abdominal distension and signs of intestinal obstruction and abdominal sonography showed a jejunojejunal intussusceptions which was confirmed at laparotomy. Interestingly, no lead point was found. Rather 8cm of bowel distal to intussuscepted segment was found to be gangrenous bowel. Resection with Bishop Koop anastomosis done for the baby resulted in good outcome. The case is being presented for rare presentation of a rare surgical condition in a neonate with an endeavour to establish etiology for its occurrence.

© This is an open access article distributed under the terms of the Creative Commons Attribution License (<https://creativecommons.org/licenses/by/4.0/>) which permits unrestricted use, distribution, and reproduction in any medium, provided the original author and source are credited.

## 1. Background

Intussusception is a common abdominal emergency occurring in children between 6-18 months. The commonest site for the same is usually ileoileal or ileocolic, while jejunum is a very rare site. In contrast to its classic presentation in infants, clinical features of neonatal intussusception are difficult to recognize leading to delay in diagnosis and subsequent increased morbidity and mortality. Though a rare cause, intussusception needs to be considered as a differential diagnosis of neonatal intestinal obstruction and more often than not, a lead point is noted.<sup>1</sup> The intestinal obstruction in neonates is most often associated with atresia along with mesenteric defects and other condition causing strangulated obstruction of intestinal tract (e.g. volvulus, internal hernia, gastroschisis).<sup>2</sup> However, intussusception rarely can cause neonatal intestinal obstruction (in 0.3% to 1.3% of all cases of neonatal intestinal obstruction).<sup>2</sup>

We are presenting here a very rare case of neonatal intestinal obstruction caused by

jejunojejunal intussusceptions, where unexpectedly no lead point was identified.

## 2. Case Report

### 2.1. Case History

A twelve days old full term male neonate presented with abdominal distention of 24 hours duration and single episode of bilious vomiting. The neonate had cried immediately after birth, liquor was clear, had passed urine and meconium within 24 hrs. At presentation, the baby was lethargic and was not accepting feeds. Total leucocyte count was increased, differential leucocyte count shows neutrophilia with borderline platelet counts. Blood gases showed mild acidosis and culture showed no growth. The vitals were stable. On abdominal examination there were visible and palpable small bowel loops. The baby passed stools with rectal stimulation while nasogastric aspirates had high bilious output. X-ray abdomen showed dilated bowel loops in upper abdomen with no gas in pelvis (Figure 1). Ultrasonography of abdomen revealed telescoping of a jejunal loop into another jejunal loop (size 2.9x1.8 cm), increased internal vascularity

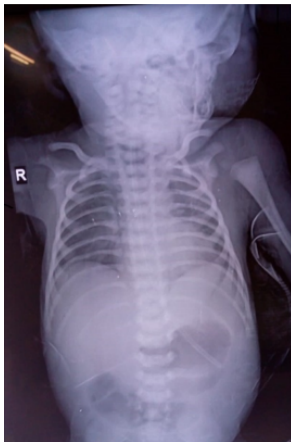\* Corresponding author.

E-mail address: [drsujoyneogi@yahoo.com](mailto:drsujoyneogi@yahoo.com) (S. Neogi).

of the involved segment of jejunum with mild free fluid in the abdomen.

## 2.2. Management

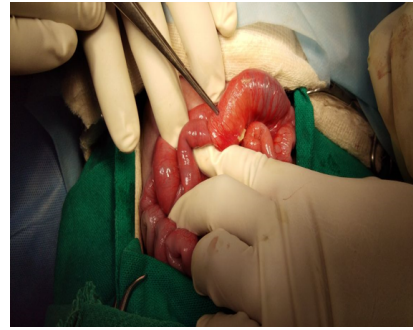
In view of the clinical condition and investigations, the decision to perform laparotomy was taken. We found a jejunojejunal intussusception (a segment of about 3 cm) which was about 20 cm distal to duodeno-jejunal junction (Figure 2). Just distal to this, a segment of about 8 cm of jejunum was found to be gangrenous with multiple patchy areas of congestion. The peritoneal cavity had minimal free fluid but no bowel perforation was detected. The intussuscepted segment was resected as it was irreducible. No lead point could be detected on gross examination. Remaining bowel and viscera was unremarkable. Following resection of gangrenous part, Bishop Koop stoma with transanastomotic tube (TAT) was made (Figure 3). The histopathology of the resected jejunum showed scattered areas of mucosal ulceration, hyperemia and villous atrophy with hemorrhagic necrosis and leucocytic infiltration suggestive of ischemic necrosis. There was no evidence of lead point.



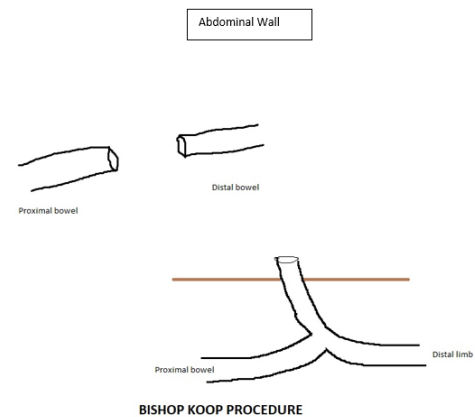
**Fig. 1:** X-ray of chest and abdomen showing dilated upper small bowel loops

## 2.3. Follow up

The baby was started on total parenteral nutrition (TPN) in the post-operative period and subsequently feeding through TAT was started on 5<sup>th</sup> post operative day (POD) and was gradually increased. The baby was shifted to oral feed from 10<sup>th</sup> POD, which was tolerated well. There was a superficial dehiscence and minor leak of fecal contents which was managed conservatively. The baby was discharged on full oral breast feeds. The baby is asymptomatic and doing well at 6 month follow up.



**Fig. 2:** Operative photograph showing jejuno-jejunal intussusception



**Fig. 3:** Illustration of Bishop Koop procedure

## 3. Discussion

The common causes of intestinal obstruction in neonates are small intestinal atresia or stenosis, malrotation, antenatal adhesions, meconium ileus, meconium plug syndrome, anorectal malformation, Hirschsprung disease and ileus related to sepsis.<sup>3</sup> Intussusception is the most common cause of intestinal obstruction in children between 6 to 18 months but is quite rare in neonates where it contributes to only 0.3%<sup>4</sup> of all cases. Of about 6000 published cases of intussusceptions in pediatric population, only 28 occurred in neonates.<sup>5,6</sup> In all age groups including neonatal period, the most common site of intussusception is ileocolic junction. Small bowel intussusception accounts of less than 10% cases of intestinal obstruction in all age groups. Of these the occurrence of jejunal intussusception and that too in neonates have been rarely reported.<sup>7</sup>

Classically intussusception in young infants is said to be initiated by hypertrophy of Peyer's patches in distal ileum in young infants.<sup>8</sup> In full term neonate with intussusception, a lead point is present in approximately as high as 58% of patients, such as duplication cyst, hamartoma, Meckel's diverticulum, or mesenchymoma.<sup>9</sup> In the neonate reported by us a possibility of local jejunitis leading

to some mucosal or lymphoid hypertrophy and initiating the process of intussusception was considered. But there was no evidence of any lead point or documentation of lymphoid hypertrophy either pre/per operatively or on histopathological examination of the excised specimen. The presence of patchy gangrene of jejunum and its increased vascularity and presence of mild fluid point towards the likelihood of inflammatory event as the cause of jejunal intussusception in our patient as have also been postulated by other workers for small bowel intussusception in infants and older children.<sup>10</sup>In absence of any clear cut lead point, we postulate that the underlying mechanism in our patient could be due to local peristaltic abnormalities caused by inflammation as 'hyperperistalsis' has been postulated as underlying phenomenon of intussusception by some other authors also.<sup>11</sup>

The occurrence of antenatal intussusception has generally been considered as preceding event leading to jejunal atresia in the neonate by causing vascular compromise and absorption of affected bowel segment.<sup>10</sup> However, in the patient described herein the absence of discontinuity of jejunal lumen and/or any mesenteric defect despite a relatively longer duration of symptoms did not resulted, this may indirectly hints that the antenatal event from occurrence of intussusception to formation of atresiamust be taking long time. Our intervention interrupted the progression towards total vascular ischemia of the involved segment and did not result in severe compromise of the vascularity of the involved segment.

The surgical intervention done by us was similar to what would have been done for a neonate with high jejunal atresia and led to good outcome.

#### 4. Conclusion

We conclude that intussusception at an uncommon site (jejunum) without any lead point in a neonate could be due to peristaltic alteration caused bylocal inflammation in our case presented and these points make this case striking

#### 5. Source of Funding

No financial support was received for the work within this manuscript.

#### 6. Conflict of Interest

The authors declare they have no conflict of interest.

#### References

1. Parelkar SV, Sanghvi BV, Vageriya NL, Paradkar B, Samala DS, Oak SN, et al. Neonatal jejunal polyp with jejunojejunal intussusception causing atresia: A novel cause. *J Pediatr Surg Case Rep.* 2014;2(2):73–5. doi:10.1016/j.epsc.2014.01.008.
2. Rachelson MH, Jernigan JP, Jackson WF. Intussusception in the newborn infant. *J Pediatr.* 1955;47(1):87–94. doi:10.1016/s0022-3476(55)80127-8.
3. Frischer JS, Azizkhan RG. Jejunoileal atresia and stenosis. In: Coran A, Adzick N, Krummel T, editors. *Pediatric Surgery*. Philadelphia, USA: Elsevier Saunders; 2012. p. 1059–72.
4. Wang NL, Yeh ML, Chang PY, Sheu JC, Chen CC, Lee HC, et al. Prenatal and neonatal intussusception. *Pediatr Surg Int.* 1998;13(4):232–6. doi:10.1007/s003830050305.
5. Deshmukh SD, Bavikar R, Naik AM. Jejunal Atresia in a Neonate due to Intrauterine Intussusception. *Indian Pediatr.* 2012;49:149–50.
6. Price KJ, Robertson NR, Pearse RG. Intussusception in preterm infants. *Arch Dis Child.* 1993;68:41–2. doi:10.1136/adc.68.1\_spec\_no.41.
7. Lewis JH. Jejunal intussusception of the newborn. *Am J Dis Child.* 1939;58(3):558–63.
8. Kennedy M, Liacouras CA. Intussusception. In: Kliegman R, Stanton B, Schor N, editors. *Neelson textbook of Pediatrics*. Philadelphia, PA: Elsevier Saunders; 2011. p. 1287–89.
9. Patriquin HB, Atshani E, Effman E, Griscom NT, Johnson F, Kramer SS, et al. Neonatal Intussusception. *Radiol.* 1977;125(2):463–6. doi:10.1148/125.2.463.
10. Talwalker VC. Intussusception in the newborn. *Arch Dis Child.* 0192;37(192):203–8.
11. Spiro DM, Arnold DH, Barbone F. Association Between Antibiotic Use and Primary Idiopathic Intussusception. *Arch Pediatr Adolesc Med.* 2003;157(1):54–9. doi:10.1001/archpedi.157.1.54.

#### Author biography

**Simmi K Ratan**, Professor

**Ashish Kumar**, Senior Resident

**Shashank Shekhar Panda**, Associate Professor

**Sujoy Neogi**, Associate Professor

**Cite this article:** Ratan SK, Kumar A, Panda SS, Neogi S. Jejuno-jejunal intussusception in a neonate without any lead point: A rare case report. *IP Int J Med Paediatr Oncol* 2020;6(4):175-177.