

Content available at: <https://www.ipinnovative.com/open-access-journals>

IP International Journal of Medical Paediatrics and Oncology

Journal homepage: <https://www.ipinnovative.com/journals/IJMPO>

## Case Report

# Pulmonary agenesis with VACTERL association: A rare case with review of literature

Ramesh Choudhary<sup>1,\*</sup>, Ashok Gupta<sup>1</sup>, Vivek Kumar Athwani<sup>1</sup>, Vidhi Kotiya<sup>1</sup>

<sup>1</sup>Dept. of Paediatrics, SMS Medical College, Jaipur, Rajasthan, India



### ARTICLE INFO

#### Article history:

Received 20-12-2020

Accepted 30-12-2020

Available online 09-01-2021

#### Keywords:

Congenital abnormalities

neonate

agenesis

VACTERL

### ABSTRACT

Pulmonary agenesis is an extremely rare congenital malformation with an estimated frequency of 1 in 10000-15000 autopsies and 34 per million live births. In 50% cases it is associated with other malformations i.e. cardiovascular, musculoskeletal, gastrointestinal and renal. We report a rare case of a male neonate with right pulmonary agenesis associated with VACTERL sequence (L5 hemi-vertebra, right absent kidney with left ectopic kidney and right radial agenesis). This association was never reported in published literature.

© This is an open access article distributed under the terms of the Creative Commons Attribution License (<https://creativecommons.org/licenses/by/4.0/>) which permits unrestricted use, distribution, and reproduction in any medium, provided the original author and source are credited.

## 1. Case Report

A 35-w small for gestational age (SGA) male neonate was born to 25-y-old mother by non-consanguineous marriage with uneventful antenatal period. Baby was referred for respiratory distress soon after birth and had right upper limb deformity (Figure 1A). Baby had absent breath sound over right hemi-thorax and respiratory distress, managed with continuous positive airway pressure (CPAP) ventilation. On cardiac examination heart sounds were shifted to right with no evidence of murmur and pulses were palpable in all 4 limbs. Chest radiography showed opaque right hemi-thorax with ipsilateral mediastinal shift; initially managed as pneumonia. Sepsis screen and pulse oximetry screening was negative. In view of congenital malformations, infantogram done showed hypoplastic ulna, absent radius and thumb; L5 hemi-vertebra and non-resolving opacity on right hemithorax (Figure 1B). Ultrasound abdomen showed left ectopic kidney in left iliac region with absent right kidney and ultrasound chest showed absent lung tissue on right hemi-thorax. These were confirmed on computed tomography (Figure 1C). Echocardiography

showed structurally normal heart with right shifting of heart. Ophthalmological and hearing screening was normal. Neonate was discharged on 8-d of life in stable condition with advice of regular multi-disciplinary follow up.

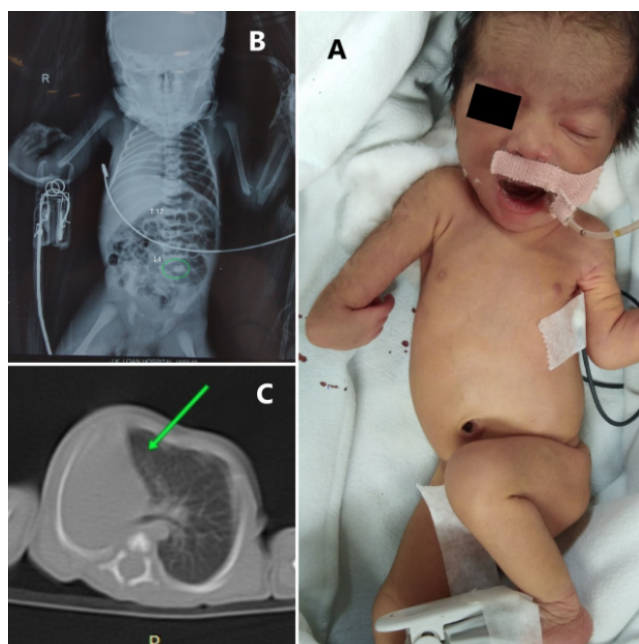
## 2. Discussion

Pulmonary agenesis (PA) is extremely rare congenital malformation of lung development with sporadic occurrence; though parental consanguinity was also reported.<sup>1</sup> First case of PA was described by De Pozze in 1673 on autopsy in adult female.<sup>2</sup> This results from development arrest or development imbalance between lung buds in early embryological life. Boyden<sup>3</sup> classified PA into 3 categories on the basis of development of lung bud, (i) agenesis, in which there is complete absence of lung tissue, bronchus and blood supply to affected side (ii) aplasia, in which rudimentary bronchus is present but no lung tissue is present, and (iii) hypoplasia, in which variable amount of lung parenchyma, bronchial tree, and vasculature are present and under-developed.

PA affects left lung and male predominantly. Cases of isolated PA are recognized incidentally during routine examination or due to recurrent respiratory infections or

\* Corresponding author.

E-mail address: [drrameshchoudhary@yahoo.co.in](mailto:drrameshchoudhary@yahoo.co.in) (R. Choudhary).



**Fig. 1:** (A) Picture of 35weeks male neonate showing hypoplastic right forearm; (B) Radiogram showing opaque right hemi-thorax with herniation of left lung, hypoplastic right ulna with absent radius and thumb bone, L5 hemi-vertebra (green circle); (C) Cut section of CT chest confirming findings of chest radiogram suggestive of pulmonary agenesis.

pneumothorax.<sup>4-6</sup> Children with associated malformation are usually recognized early.

Presently, Contrast CT is standard investigation to diagnose and differentiate from other forms of mal-development; bronchoscopy and pulmonary angiography are rarely needed. Typical CT findings are opaque hemi-thorax with mediastinal shift towards affected side with absence of lung parenchyma, pulmonary artery and bronchial tree, as seen in our case.<sup>4</sup> This may mimic pleural effusion, consolidation, collapse or diaphragmatic hernia. In absence of strong clinical suspicion; diagnosis of PA may be missed leads to mismanagement and even mortality. Reports are available as these patients were tried for pleural aspiration or treated as recurrent pneumonia.<sup>4</sup>

PA is associated with other malformation in 50% cases and seen more with right sided agenesis. Among cardiovascular malformations, patent ductus arteriosus, septal defects and tetralogy of fallot; in musculoskeletal abnormalities hemi-vertebrae, absence of ribs or radius, in digestive tract, tracheoesophageal fistula and imperforate anus; in renal anomalies absent or polycystic kidney are commonly seen.<sup>2,4,6</sup>

PA with VACTERL sequence (L5 hemi-vertebra, right absent kidney with left ectopic kidney and right radial agenesis), as seen in our case, was never reported in published literature. VACTERL association is defined by

presence of at least three of the following: vertebral defects, anal atresia, cardiac defects, tracheo-esophageal fistula, renal anomalies and limb abnormalities.<sup>7</sup>

The exact etiology of PA remains unknown, but it may be the result of one or multiple factors i.e. genetic, intrauterine infections, teratogenic insults, vitamin A deficiency and mechanical insult. In our case, right PA, right renal agenesis with left ectopic kidney, L5 hemi-vertebra and right radial agenesis might be a result of unilateral mesodermal defect caused by an unknown agent.

Management of PA is essentially symptomatic. Asymptomatic cases don't require intervention, however early and aggressive treatment of lung infection is required. Pulmonary hypertension is an early complication that requires attention. Significant mediastinal shift may require inflatable prosthesis placement or diaphragmatic translocation and/or aortopexy.<sup>4,8</sup> Hemi-vertebra is the most common etiology of congenital scoliosis, it usually requires surgical correction if located from thoracolumbar to lumbo-sacral junction. So, multi-disciplinary follow up is required.<sup>9</sup> Palivizumab prophylaxis for respiratory syncytial virus and vaccination for influenza and pneumococcal infections are recommended.<sup>5</sup>

Bilateral agenesis is incompatible with life; however it is entirely compatible in unilateral agenesis, if present on left side and not associated with other malformations. Cardiac malformations affects prognosis to a greater extent and right-sided agenesis has a poor prognosis due to carinal mal-rotation, distortion of bronchi and vascular structures, and deviation of heart and mediastinum.<sup>6</sup> More than 50% PA patients die before first 5-y of age.

### 3. Conclusion

PA is extremely rare congenital malformation and never reported before as seen in our case. Strong suspicion and recognition of PA is required to prevent mismanagement and mortality.

### 4. Acknowledgements

The authors are grateful to the patient and his family for their precious cooperation in this clinical brief.

### 5. Author's Contributions

RC: gave the clinical concept for this paper. VK: involved in clinical care and procured patient details. VKA: drafted the initial manuscript and all authors were involved in revision and final drafting. AG: Critical revision and will act as overall guarantor.

### 6. Source of Funding

None.

## 7. Conflict of Interest

None.

## References

- Mardini MK, Nyhan WL. Agenesis of the lung: Report of four patients with unusual anomalies. *Chest*. 1985;87:522–7.
- Kayemba-Kay's S, Couvrat-Carcuzon V, Goua V, Podevin G, Marteau M, Sapin E, et al. Unilateral pulmonary agenesis: A report of four cases, two diagnosed antenatally and literature review. *Pediatr Pulmonol* . 2014;49(3):E96–E102. doi:10.1002/ppul.22920.
- Boyden EA. Developmental anomalies of the lungs. *Am J Surg*. 1955;89(1):79–89. doi:10.1016/0002-9610(55)90510-9.
- Mohan A, Guleria R, Sharma R, Das C. Unilateral pulmonary agenesis: an uncommon cause of lower zone lung opacity. *Indian J Chest Dis Allied Sci*. 2005;47:53–6.
- Kant S. Unilateral pulmonary hypoplasia - A case report. *Lung India*. 2007;24(2):69–71. doi:10.4103/0970-2113.44215.
- Tyagi R, Chowdhary G. Unilateral lung agenesis: a case report and literature review. *Egypt J Bronchol*. 2018;12:486–8.
- Solomon BD. VACTERL/VATER Association. *Orphanet J Rare Dis*. 2011;6:56.
- Chopra K, Sethi GR, Kumar A. Pulmonary agenesis. *Indian Pediatr*. 1988;25:678–82.
- Johal J, Loukas M, Fisahn C, Chapman JR, Oskouian RJ, Tubbs RS, et al. Hemivertebrae: a comprehensive review of embryology, imaging, classification, and management. *Childs Nerv Syst* . 2016;32(11):2105–9. doi:10.1007/s00381-016-3195-y.

## Author biography

**Ramesh Choudhary**, Associate Professor

**Ashok Gupta**, Senior Professor

**Vivek Kumar Athwani**, Medical Officer

**Vidhi Kotiya**, Post Graduate

**Cite this article:** Choudhary R, Gupta A, Athwani VK, Kotiya V. Pulmonary agenesis with VACTERL association: A rare case with review of literature. *IP Int J Med Paediatr Oncol* 2020;6(4):172-174.