



Original Research Article

Unclassified variants of hepatic artery discovered on a 40 slice multidetector CT scanner

Sachal Sharma^{1,*}, Namita Singh², Payal Malhotra³, Murtaza Kamal⁴¹Bl Kapoor Super-Speciality Hospital, New Delhi, India²INMAS, New Delhi, India³Rajiv Gandhi Cancer Institute and Research Center, New Delhi, India⁴Star Hospitals, Hyderabad, Telangana, India

ARTICLE INFO

Article history:

Received 16-04-2020

Accepted 30-05-2020

Available online 18-07-2020

Keywords:

Hepatic artery

Multidetector CT scanner

ABSTRACT

CT angiography is a common modality used to study the anatomy of hepatic arterial system. Literature reports various unclassified variants of hepatic artery, which prompted us to take this study to see the same in our cohort of population. CT angiograms were performed using 40 slice CT scanner on 110 patients for the investigation of arterial variants in case of hepatic donors and patients for aortic evaluation with angiography. The Results were analyzed as per Michels as well as Modified Michels / Hiatt classification of Hepatic artery variants. The typical/classical most common anatomy (type I variant) as proposed by Michels in 1955, was Right and left hepatic artery arising from common hepatic artery which is a branch of celiac artery. In our study we did not find any type X variant and more so vascular anatomy in 5 patients (8%) did not fit into Michels' classification or Modified Michels/Hiatt classification. These variants have not been reported before, and its importance lies in the fact that variants can predispose to increased risk of surgical complications during liver transplantation and hepatobiliary surgery. It may also influence the choice of vascular technique and materials used in interventional procedures.

© 2020 Published by Innovative Publication. This is an open access article under the CC BY-NC license (<https://creativecommons.org/licenses/by-nc/4.0/>)

1. Introduction

Liver has a dual blood supply, and receives its supply from the CHA and portal vein. CHA divides at the posterior part or pylorus or at first part of the duodenum to give rise to the gastroduodenal artery. It then advances to portal hilum as the proper hepatic artery. At hilum, the hepatic artery proper gives off the right hepatic artery entering the right lobe of liver, a left hepatic artery entering the left lobe and a small middle hepatic entering the quadrate lobe of the liver (which is not always identified).¹

The morphologic variations in CHA may arise at its origin and /or at branching pattern with later being more common. Hepatic artery is called as an 'aberrant hepatic artery(AHA)' if it arises from a source other than the terminal end of the celiac trunk² and it may be accessory

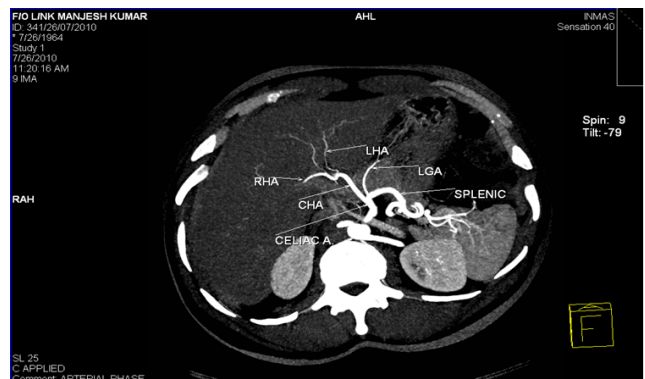


Fig. 1: Normal hepatic arterial anatomy with right hepatic artery(RHA) and left hepatic artery (LHA) arising from common hepatic artery(CHA)

* Corresponding author.

E-mail address: drsachal@gmail.com (S. Sharma).

or replaced. The accessory hepatic artery is termed from the source of its origin.³ The term accessory hepatic artery is called when the native left hepatic artery also exist having its origin from celiac trunk apart from the second hepatic artery supplying the same lobe. Replaced hepatic artery is termed when the hepatic artery supplying the lobe is single and not arising from celiac trunk.

Normal hepatic arterial branching system is found in 60% of the population, the rest of 40% have aberrant arterial system. Among the aberrant arterial system right hepatic artery originating from the superior mesenteric artery (10–12% of individuals) is the most common variation. The origin of common hepatic artery from the superior mesenteric artery in 2.5% of the population. The origin of left hepatic artery directly from the abdominal aorta in 2.5% of the population.⁴

2. Materials and Methods

A total of 110 patients underwent the study on Siemens Somatom Sensation 40. Patients underwent only post contrast acquisition of data with slice thickness of 5mm from the dome of the diaphragm till the pelvis. Thin reconstructions of images done in axial, coronal and sagittal planes. Gantry rotation of 0.5 sec per rotation with a pitch of 0.9mm used. Bolus tracking technique with an automatic injector at a rate of 3-4ml/sec. Estimated dose of contrast is 1-1.5ml/kg/body wt of the patient is used. The images obtained were transferred to a workstation for analysis. Maximum intensity projection (MIP) and multiplanar reconstruction (MPR) and volume rendered images were used for evaluation and analysis of vascular system.

Data obtained by MDCT angiography and the post processed images were evaluated by two radiologists. The average time consumption to do the post processing was app 15-20 minutes. The normal as well as the variant hepatic arterial anatomy was studied and recorded.

The initial raw data acquired from the acquisition determines the diagnostic accuracy of MDCT angiography. Accurate timing of acquisition, proper amount of contrast injection and proper patient preparation as well as positioning play a pivotal role in study acquisition.

3. Results

Comparison of Michels' data with the current series (Table 1) shows a somewhat different incidence of variant patterns in Michels' patients. We did not observe Michels' Type X (common hepatic artery from left gastric artery), whereas Michel did not observe Hiatt Type VI (common hepatic artery from aorta). Some newer variants not described in any of the two classification system are found in the current study.

Out of total of hundred and ten (110) patients undergoing CT angiography hundred and five(105) patients had anatomy described by Michel. Five(5) patients had anatomy not described by Michels or Hiatt study.

3.1. Results are tabulated as follows

Table 1: Distribution of hepatic artery variation in general population

Michels types	% in terms of Michels type	Current Study (%)
I	55%	72(68.57%)
II	10%	3(2.85%)
III	11%	7(6.66%)
IV	01%	3(2.85%)
V	08%	9(8.57%)
VI	07%	06(5.71%)
VII	01%	01(0.95%)
VIII	02%	03(2.85%)
IX	2.5%	01(0.95%)
X	0.5%	0.00

3.2. Results as per michels classification

Table 2: Comparison of current study with Hiatt classification

HIATT Types	HIATT Types (%)	Current Study (%)
I	75.8	68.57
II	9.7	11.42
III	10.6	12.37
IV	2.3	6.65
V	1.5	0.95
VI	0.2	0.95

3.3. NEWER VARIANTS detected in our study

1. Common hepatic artery (CHA) arising from superior mesenteric artery (SMA) and Accessory Left Hepatic Artery from Left Gastric Artery(LGA).

2. Right hepatic artery(RHA) and Left hepatic artery(LHA) arising directly from celiac trunk and an accessory Left Hepatic Artery (acc. LHA) from Left gastric artery(LGA).

3. Common hepatic artery (CHA) arising from Superior mesenteric artery (SMA) and an accessory Right hepatic artery (acc. RHA) arising from SMA.

4. Left Hepatic artery (LHA) arising from Gastroduodenal artery (GDA),an accessory left hepatic artery arising left gastric artery and Right hepatic artery arising directly from celiac trunk.

5.Common hepatic artery (CHA) arising directly from celiac trunk, another right hepatic branch arising from celiac

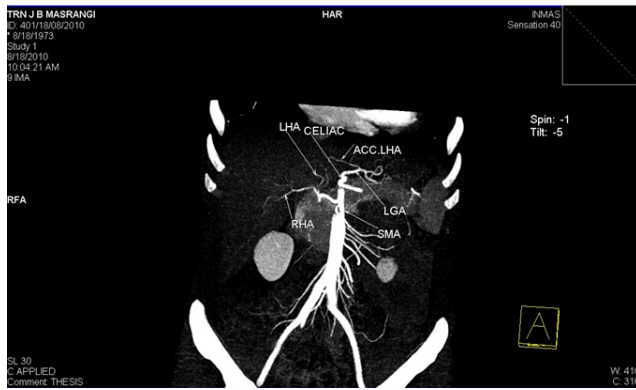


Fig. 2: CHA arising from SMA and Accessory LHA from LGA.

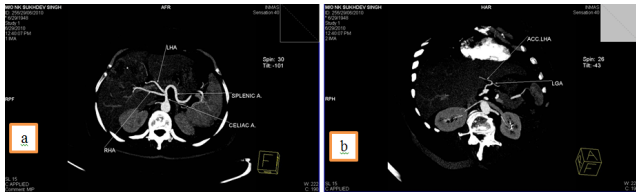


Fig. 3: a: RHA and LHA from Celiac trunk, 2b: Accessory LHA from LGA

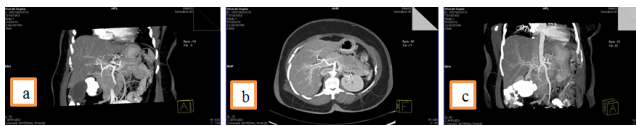

Fig. 4: a: CHA from SMA, 3b: Accessory RHA from SMA, 3c: CHA arising from SMA and an accessory RHA from SMA.

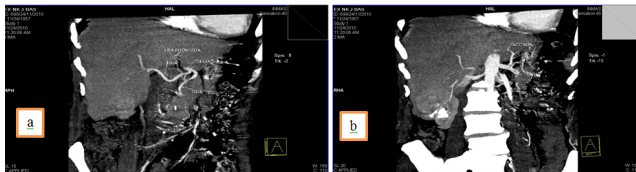


Fig. 5: LHA arising from GDA and RHA from celiac trunk, 4b: Accessory LHA from LGA

trunk or a double right hepatic artery and an accessory left hepatic artery arising from Left gastric artery(LGA)

4. Discussion

The evolution of newer advancements and medical techniques in the management of hepatic lesions and liver transplantation has validated the recognition of normal as well as variant anatomy of the hepatic arterial system for surgical precisions and to reduce the associated co morbidities. More over the newer variants that are not described in the classification system encourage the need for a new classification that can accommodate these newer

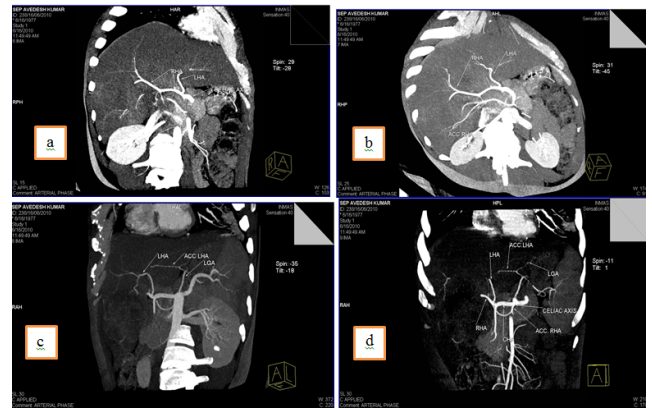


Fig. 6: a: CHA from celiac trunk, 5b: Accessory RHA from celiac trunk, 5c: Accessory LHA from LGA, 5d: CHA from celiac trunk, accessory RHA from celiac trunk and accessory LHA from LGA.

variants. The variations in hepatic arterial system can be critical in the current advances in the treatment of hepatic pathologies.

The increasing efficacy of hepatic artery infusional chemotherapy have been shown in the recent in controlling and treating hepatic diseases.⁵ During the procedure of hepatic arterial infusional chemotherapy the catheter tip is surgically placed via an arteriotomy in gastroduodenal artery at the junction of gastroduodenal and common hepatic artery. In order to achieve the goal of uniform perfusion of chemotherapeutic agent throughout the liver the recognition of any variant anatomy of hepatic arterial system is essential so that the procedure can be manipulated.⁵ In the patients with variant arterial anatomy, vascular reconstruction or use of double port catheter pumps are used to attain uniform perfusion.⁶

Double hepatic arterial variant which is not included in the Michels classification has a particular relevance with respect to catheter position and number of catheters so as to achieve an ideal uniform distribution of chemotherapeutic agent.⁷

In the clinical scenario of a liver transplant patient apart from hepatic and portal venous anatomy, hepatic arterial anatomic variations play a pivotal role. All hepatic arterial variations need to be evaluated for preservation and revascularization to avoid parenchymal ischemic and biliary tract abnormalities.⁸ Adequate knowledge of hepatic arterial anatomy is very crucial for selection of patients for living related liver transplantation(LRLT) and MDCT is the mainstay in preoperative evaluation of classical and variable hepatic arterial anatomy. Knowing the left lobe arterial supply and segment IV arterial supply is critical in ensuring optimal donor hepatectomy and proper graft vascularization. The major concern in hepatic arterial variation in preoperative evaluation is aberrant LHA arising from left gastric artery, in the cases where left lobe of

liver is used as a graft.⁹ Moreover surgical approach can be modified as per the the preoperative knowledge of anomalous vessels.¹⁰ During the transplant operative procedures post operative arterial complications can be anticipated with more complicated graft reconstructions and appropriate post op measures can be taken to overcome them.⁸ Multiple arterial anastomosis can lead to technical difficulties that can lead to multiple complications such as biliary stricture, cholangitis, cholangiolar abscesses and graft rejection as the biliary ducts are vascularized only by the hepatic arteries.¹¹ Segment IV artery arising from right hepatic artery is important in case of right lobe liver transplantation as it need to be spared during the operative procedure so as not to induce ischemic changes in the donor liver.¹²

Trauma to hepatic parenchyma and hepatic arterial trauma is a known entity during blunt trauma abdomen.¹³ In case of traumatic liver hematoma arising from an aberrant hepatic artery it may pose a potential diagnostic error during conventional angiography.¹⁴ Preoperative evaluation of hepatic arterial anatomy has attained a pivotal role in laparoscopic cholecystectomy.¹¹ Biliary and vascular injuries though uncommon, but are known entities encountered in laproscopic cholecystectomy.¹⁵ Variant arterial anatomy increases the chances of such arterial injuries. Knowing the hepatic arterial anatomy can very well avoid the arterial injury and measures can be taken to preserve the vessels.¹⁶

5. Source of Funding

None.

6. Conflict of Interest

None.

References

- Gray H, Ferguson M. Abdominal aorta. Churchill Livingstone; 1995. p. 1548–53.
- Michels NA. Blood supply and anatomy of the upper abdominal organs with a descriptive atlas. Philadelphia: JB Lippincott. 1955;p. 136–7.
- Healey JE, Schroy PC, Serensen RJ. The intrahepatic distribution of the hepatic artery in man. *J Internat Coll Surg*. 1953;22:133.
- Tuncay H. Mesenteric Arterial Variations Detected at MDCT Angiography of Abdominal AortaDOI. *AJR*. 2009;192:1097–1102.
- Winston CB, Lee NA, Jarnagin WR, Teitcher J, DeMatteo RP, Fong Y, et al. CT Angiography for Delineation of Celiac and Superior Mesenteric Artery Variants in Patients Undergoing Hepatobiliary and Pancreatic Surgery. *American Journal of Roentgenology*. 2007;189(1):W13–9.
- Eid A, Reissman P, Zamir G, Pikarsky AJ. Reconstruction of replaced right hepatic artery, to implant a single-catheter port for intra-arterial hepatic chemotherapy. *Am Surg* . 1998;64:261–2.
- Convey AM, Brody LA, Maluccio MA, Getrajdman GI, Brown KT. Variant Hepatic Arterial Anatomy Revisited: Digital Subtraction Angiography Performed in 600 patients. *Int Radiol J*. 2002;222(4).
- Soin AS, Friend PJ, Rasmussen A, Saxena R, Tokat Y, Alexander GJM, et al. Donor arterial variations in liver transplantation: Management and outcome of 527 consecutive grafts. *Br J Surg* . 1996;83(5):637–41.
- Todo S, Makowka L, Tzakis AG. Hepatic artery in liver transplantation. *Transplant Proc*. 1987;19:2406–11.
- Volpe CM, Peterson S, Hoover EL, Doerr RJ. Justification for visceral angiography prior to pancreaticoduodenectomy. *Am Surg*. 1988;64:758–61.
- Jones RM. The hepatic artery:a reminder of surgical anatomy. *J R Coll Surg Edinb*. 2001;46:168–70.
- Duran C, Uraz S, Kantarci M, Ozturk E, Doganay S, Dayangac M, et al. Hepatic Arterial Mapping by Multidetector Computed Tomographic Angiography in Living Donor Liver Transplantation. *Journal of Computer Assisted Tomography*. 2009;33(4):618–25.
- Mesenteric artery, secondary to blunt trauma. *J Trauma*. 2000;48:325–31.
- Konstam MA, Novelline RA, Athanasoulis CA. Aberrant hepatic artery: A potential cause for error in the angiographic diagnosis of traumatic liver hematoma. *Gastrointest Radiol* . 1979;4(1):43–5.
- Deziel DJ, Millikan KW, Economou SG, Doolas A, Ko ST, Airan MC, et al. Complications of laparoscopic cholecystectomy: A national survey of 4,292 hospitals and an analysis of 77,604 cases. *Am J Surg* . 1993;165:9–14.
- Biehl TR, Traverso LW, Hauptmann E, Ryan JA. Preoperative visceral angiography alters intraoperative strategy during the whipple procedure. *Am J Surg* . 1993;165(5):607–12.

Author biography

Sachal Sharma Consultant

Namita Singh Consultant

Payal Malhotra Consultant

Murtaza Kamal Consultant

Cite this article: Sharma S, Singh N, Malhotra P, Kamal M. **Unclassified variants of hepatic artery discovered on a 40 slice multidetector CT scanner.** *IP Int J Med Paediatr Oncol* 2020;6(2):52-55.