

## The neuroblastoma: A case report and review

Ahmed Ullah Khan<sup>1\*</sup>, Mohammed Yaseen<sup>2</sup>, U. Narayan Reddy<sup>3</sup>

<sup>1</sup>Associate Professor, <sup>2</sup>Senior Resident, <sup>3</sup>Professor and HOD, <sup>1-3</sup>Dept. of Pediatrics, Deccan College of Medical Sciences, Owaisi Group of Hospitals, Hyderabad, Telangana, India

\*Corresponding Author: Ahmed Ullah Khan

Email: [ahmedkhan67353@gmail.com](mailto:ahmedkhan67353@gmail.com)

### Abstract

A 13 year old boy brought to Pediatric intensive care unit with chief complaints of Pain in both the lower limbs since 8 days followed by irritability since 5 days and difficulty in walking over a period of 2 days. Ultrasound guided fine needle aspiration of left cervical LN reveals diffuse infiltrates of atypical cells which are larger than lymphocytes with irregular nuclear borders and chromatin clumping. Some of the cells are pleomorphic. Mass lesion in the right suprarenal and renal region with enlargement and infiltration of right kidney and retroperitoneal lymphadenopathy with encasement of renal vessels, celiac and superior mesenteric arteries and Likely – Right sided adrenal supra renal Neuroblastoma.

**Keywords:** Neuroblastoma, Pediatrics, Pediatric oncology, Chemotherapy.

### Introduction

Neuroblastoma one of the commonest neurologic tumor of paediatrics and child hood found anywhere along the peripheral sympathetic nervous system, some times also known as extra cranial solid tumors of infancy. It was first described by Dr. Rudolf Virchow as a “Glioma” in the abdominal cavity. Average of 1/7000 live births are at the prevalence of Neuroblastoma. Incidence of Neuroblastoma was 10 cases per 1 million per year in younger children. The median age of children at diagnosis is 22 months and 90% cases are diagnosed by 5 years of age.

Stages for Neuroblastoma:-

Stage 1: Tumor limited to organ or structure of origin

Stage 2: Tumor with regional spread not crossing the midline

Stage 3: Tumor crossing the midline, bilateral nodes involved

Stage 4: Distant metastasis

Stage 4s: Localized primary tumor with disseminated disease to liver, skin and/or bone marrow (in infants less than 1 year of age).

Neuroblastoma could be a malignant growth of neural crest cells that make to the sympathetic systema nervosum. It's a childhood growth occurring in infants and young kids (5 years and fewer in ninetieth of all cases) that accounts for eight to 100% of medicine cancers. It's going to arise at any web site within the sympathetic systema nervosum, most typically within the abdomen. At designation the growth is also restricted to one organ, do estically or regionally invasive, or wide disseminated. Bone, bone marrow, liver and skin are among the foremost common pathologic process sites. Malignant tumor is clinically characterised by its variable evolution. Most localized tumours have a wonderful prognosis once treated by surgical operation with or while not therapy. Infants but one year have a much better prognosis than kids not withstanding growth stage. A number of these tumours might even show spontaneous regression. In distinction, approximately hr of kids (>one year) with malignant

tumor gift pathologic process malady at designation with poor outcome, despite intensive treatment protocols as well as megatherapy with hematopoetic somatic cell transplantation. Malignant tumor mass screening in infants below one year isn't helpful since it reduces neither the incidence of pathologic process malady nor the mortality of disease. Disease free survival ranges from ninety fifth for a few localized tumours to half-hour for pathologic process malady in kids over one year. This clinical diversity correlates with varied biological and molecular factors (DNA content, amplified expression of MYCN cistron, expression of TRK neurotrophin receptors. Patients management ought to follow national or international treatment protocols/recommendations and needs a medical team like an expert within the field of medicine cancers.

### Case History

A 13 year old boy brought to Pediatric intensive care unit with chief complaints of Pain in both the lower limbs since 8 days followed by irritability since 5 days and difficulty in walking over a period of 2 days. Present History reveals that patient was apparently asymptomatic 8 days back when he developed pain in both lower limbs, which was acute in onset gradually progressive and associated with burning sensation in both lower limbs. No history of headache, fever, vomiting, dizziness, cough, difficulty in breathing, trauma and no paucity of movements in any limb But there is a past history of hospitalization 15 days back in view of bronchopneumonia got treated and patient was discharged and there were no history of TB contact and no other significant past history.

### Pathological findings

Ultrasound guided fine needle aspiration of left cervical LN reveals diffuse infiltrates of atypical cells which are larger than lymphocytes with irregular nuclear borders and chromatin clumping. Some of the cells are pleomorphic. follows the multi detector row computed tomography (MDCT) in IV contrast abdomen reveals Mass lesion in the

right suprarenal and renal region with enlargement and infiltration of right kidney and retroperitoneal lymphadenopathy with encasement of renal vessels, celiac and superior mesenteric arteries and Likely – Right sided adrenal supra renal Neuroblastoma. Excision biopsy was done and found positive for Neuroblastoma and bone scan is highly suspicious of skeletal metastasis. Classified to Grade – 4 Neuroblastoma.

### Discussion

Different treatments are needed at totally different stages of illness. Moreover, age at identification, as well as prognostic factors influence treatment methods. Patients ought to be treated following national or international treatment protocols or recommendations. Briefly, localized tumours are treated by primary surgery if possible (stage one and 2). In case of unfavourable prognostic factors, adjuvant therapy could also be indicated. Future challenges are the applying of either optimised treatment ways or novel therapies to patients World Health Organization can't be cured with the foremost intensive current approaches. On the other hand, medical aid reduction and even the necessity of surgery ought to be evaluated at intervals international protocols for patients World Health Organization have a wonderful survival rate with current treatment. The treatment of the actual stage 4S tumor could also be extraordinarily variable. About 50% are clinically "silent" tumours which can have the benefit of a "wait and see" strategy. They may regress aggressive with one treatment, however half them may have treatment, as a result of growth progression. Just in case of fast evolution, therapy, and/or radiation are indicated. Surgery of the first ought to be mentioned when growth response. In case of opso-myoclonus syndrome, treatment can also embrace corticosteroids, Immunoglobulines or adrenocorticotrophic hormone.

While on the admission of our patient was is conscious, oriented, pallor was present and localized left supraclavicular enlarged lymph node mass measuring 2.5cm, firm, non-matted, non-tender, painless with no suggestive of inflammation. No other lymphadenopathy appreciated and No icterus, cyanosis, clubbing, edema but there was generalized pain in both lower limbs, no deep/bony tenderness. No specific muscle tenderness. While the vitals and systemic examination of was found to be normal except palpable liver 1cm under right costal margin. The laboratory investigations such as Hb:9.3 gm/dl was on borderline, while others as Red blood cells BC: 3.5 millions/cumm, White blood cells:5200/cumm, platelet: 2.36 Lakhs/cumm and other hematological and biochemical parameters are within normal limits.

Ultrasound of neck was performed over the neck region and was found to be left sided cervical lymphadenopathy with hyper vascularity. While the ultrasound of abdomen revealed ill defined hyperechoic mass seen between uncinate process and right kidney showing minimal vascularity and increase in kidney size. Enlarged liver gives

an impression of hepatomegaly and there was an evident multiple enlarges lymphnodes in abdomen.

Clinically, tumours and opsomyoclonus syndrome might 1st tally to primary nervous disorder. Identification of pheochromocytoma will be suspected in presence of ductless gland tumours related to blood vessel cardiovascular disease and pulmonic metastasis. Histologically, particularly within the absence of multiplied urinary endocrine secretion, alternative blue spherical cell tumours should be excluded (rhabdomyosarcoma, PNET/ Ewing's malignant neoplastic disease, lymphoma, extrarenal Wilms' tumor, leukemia). Moreover, metastatic tumor ought to be differentiated from alternative neuroblastic tumors that are divided into 3 classic histopathologic patterns reflective a spectrum of maturation and cell differentiation: ganglioneuroma is that the absolutely differentiated, benign counterpart of the malignant, dedifferentiated metastatic tumor, whereas anglioneuroblastoma forms the intermediate tumour with immature and mature parts.

### Treatment protocols for neuroblastoma

1. Stage 1, 2a, 2b: Surgery and low dose Chemotherapy
2. Stage 4s: observation
3. Stage 3, 4: Chemotherapy, Radiotherapy
4. Autologous stem cell transplant with high dose MIBG administration has shown promise in the management of high risk/relapsed cases.

Therefore protocol regimen of etoposide, ifosfamide, doxorubicin and cyclophosphamide have shown the extensive results in reducing the supraclavicular lymphnodes swelling and patient was able to perform the day to day activities normal through the in the induction phase of 5 cycles of chemotherapy every 21 days along the maintenance therapy with 13cis retinoic acid, he suffered by chemotherapy induced nausea and vomiting which was subsided with the post chemotherapy institutional protocols. Hence the ECOG status can be determined to "1" post chemotherapy status.

### Conclusion

Patients having good prognosis and extremely well survival rate with the current intensive regimens and treatment strategies shall also be evaluated for surgery to avoid the metastasis of the tumor, so as to redefine the neuroblastoma with negative margins. Understanding the Neuroblastoma in biologics and genetics will help in the novel approaches towards the management and development of the newer therapies.

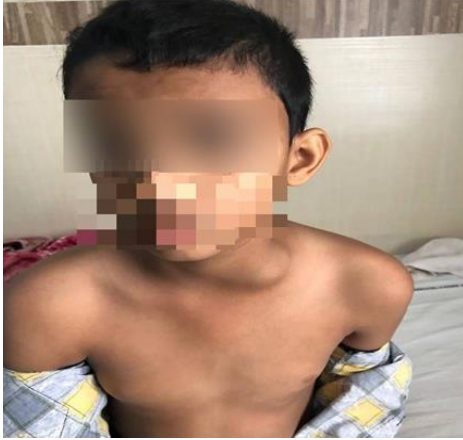

Fig. 1: Large lobular, supra clavicular mass

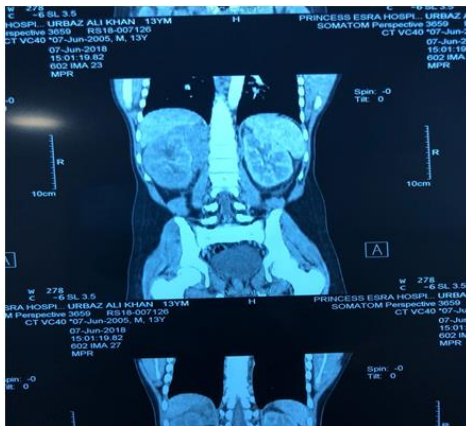

Fig. 2: Contrast MDCT Abdomen

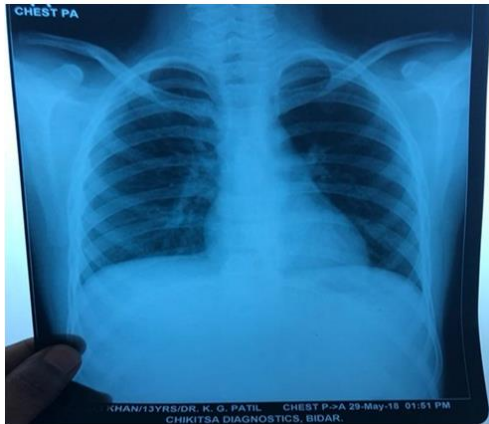


Fig. 3: X-ray was found to be normal

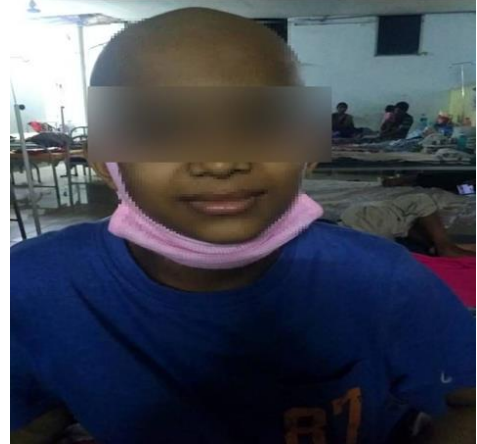

Fig. 4: Post chemotherapy reduction in size of supra clavicular mass

#### Source of funding

None.

#### Conflict of interest

None.

#### References

1. Schell M and Bergeron C. Neuroblastoma. *Orphanet Encyclopedia*.2003.<http://www.orpha.net/data/patho/GB/ukneu/roblastoma.p>.
2. Bansal, Deepak, Totadri, Sidharth, Chinnaswamy, Girish. Management of Neuroblastoma: *ICMR Consensus Document*. *Indian J pediatrics* 2017. 84. 10.1007/s12098-017-2298-0.
3. Kulkarni Ketan, Marwaha Ram. Outcome of Neuroblastoma in India. *Indian J pediatr* 2013 80. 10.1007/s12098-012-0948-9.
4. Arora R S, Eden T, Kapoor G. Epidemiology of childhood cancer in India. *Indian J Cancer* 2009;46:264-73.
5. Lall A, Bajpai M, Gupta DK. Intrarenal neuroblastoma - a diagnostic dilemma: A report of three cases. *Indian J Urol* 2001;17:170-2.
6. Mishra A, Beniwal M, Nandeesh BN, Srinivas D, Somanna S. Primary pediatric intracranial neuroblastoma: A report of two cases. *J Pediatr Neurosci* 2018;13:366-70.
7. De Bernardi B, Nicolas B, Boni L. Disseminated neuroblastoma in children older than one year at diagnosis: comparable results with three consecutive high-dose protocols adopted by the Italian Co-Operative Group for Neuroblastoma. *J Clin Oncol*. 2003;21:1592–601.
8. Spix, C., Aareleid, T., Stiller, C. Survival of children with neuroblastoma: time trends and regional differences in Europe, 1978-1992. *Eur J Cancer*. 2001;37:722–9.
9. De Bernardi B, Pistoia V, Gambini C. Peripheral neuroblastic tumors. in: R. Sheaves, P.J. Jenkins, J.A. Wass (Eds.) *Clinical endocrine oncology*. 2nd ed. Blackwell Science, Oxford, United Kingdom; 2008:360–9.
10. Agarwala, Sandeep, Neuroblastoma: Outcome over a 14 year period from a tertiary care referral centre in India. *J Pediatr Surg*. 2014;49(8)1280–5.

**How to cite this article:** Khan AU, Yaseen M, Reddy UN. The Neuroblastoma: A Case Report and Review. *Int J Med Paediatr Oncol* 2019;5(4):146-8.