

A Rare Association of Autosomal Recessive Polycystic Kidney (ARPKD) Disease with AV Canal Defect

Devendra Nema¹, Rahul Sinha^{2*}, K. Venkatnarayan³, Shamsher Dalal⁴

¹HOD, Dept. of Radiology, Military Hospital, Shillong, ²HOD, Dept. of Pediatrics, Military Hospital, Jodhpur, ³Professor & Head, Command Hospital, Pune

⁴Professor, Dept. of Pediatrics & Neonatology, Armed Forces Medical College, Pune

*Corresponding Author

E-mail: drrahul_2000@yahoo.com

Abstract

ARPKD is an autosomal recessive condition characterized by cystic dilations of the renal collecting tubules. The incidence of ARPKD is estimated to be between 1 in 10,000 - 40,000. It is the most common childhood-onset ciliopathy. The majority of patients present in infancy, although presentation can occasionally be as late as early adulthood. Extrarenal manifestations of this disorder include congenital hepatic fibrosis or Caroli disease, which involves non-obstructive dilation of intrahepatic bile ducts. We report a rare association of autosomal recessive polycystic kidney disease (ARPKD) with AV canal defect in a 3month old infant who presented with failure to thrive, abdominal distension and respiratory distress.

Key Words: Autosomal recessive, AV canal, Cyst, Polycystic.

Introduction

Autosomal recessive polycystic kidney disease is characterized bilateral and symmetrical enlargement of kidneys. The normal parenchyma is replaced by dilated collecting tubules. There is no increase in amount of connective tissue. The recurrence risk is 25%. The gene responsible for ARPKD is PKHD1 (located on chromosome 6), with most affected patients being compound heterozygotes (1, 2). Patients are often diagnosed in utero with suggestive findings of enlarged kidneys, oligohydramnios, and absence of urine in the bladder. Clinically, infants may have Potter's facies and large palpable flank masses with impaired renal function.

Other presenting features may include pulmonary insufficiency, transient hyponatremia, metabolic acidosis, and hypertension. Renal ultrasound is the usual imaging modality for confirmatory diagnosis. The ultrasound characteristically demonstrates bilaterally enlarged, echogenic kidneys with poor corticomedullary differentiation (3, 4).

Case Report

3 month old female infant brought with history of not gaining weight, abdominal distension and fast breathing and fever of 1 month duration. The infant was born to consanguineous parents by normal vaginal delivery at term. The mother was unbooked case with no antenatal scan done. There was no family history of any kidney disease or unexplained death. The baby cried immediately at birth with weight of 2kg and length of 44cm and head circumference of 33cm. Baby was started on breast feeds and was discharged on D3 of life with follow up advice. However parents brought the baby at 3 month of age with history of not gaining weight, abdominal distension and fast breathing. The

clinical evaluation revealed sick infant with weight of 2.8kg, head circumference of 34cm and length of 46cm. There was low set ears with long philtrum (Fi. 1). There was tachycardia, tachypnoea and subcostal retractions and blood pressure 100/64 mm Hg (>95th P) and infant was febrile (101°F). The SpO₂ was 94% room air. There was pallor. The systemic examination revealed bilateral distension of flanks with palpable renal mass (fig. 2). The cardiovascular system revealed pansystolic murmur Gd IV/VI with systolic thrill in left parasternal edge. There was bilateral crepts in infra axillary region. The infant was started on IV fluids, oxygen, antibiotics and lasix keeping the possibility of congestive cardiac failure and investigations were send and urgent USG abdomen was planned. The investigation revealed Haemoglobin of 9 gm%, TLC 16200 (P85, L12, M3) and platelet of 3lacs/cmm. The PBS was suggestive of polymorpho leucocytosis. The malarial parasite was negative. C reactive protein was positive. The renal function test revealed urea of 135/creatinine 3.5 and electrolytes Sr Sodium 128 and potassium 5.8/ Chloride 106/ Total Calcium 8 mg% (ionized 3.8)/ Sr Phosphorus 3.8mg%/ ALP 350IU/L. The LFT with enzymes was normal. The Albumin was 3gm% and urine examination revealed few pus cells and specific gravity of 1006. The CXR revealed cardiomegaly with pulmonary plethora, suggestive of Lt to Rt shunt. The ECG was suggestive of left ventricle hypertrophy with left axis deviation. The ultrasound of kidney revealed bilateral enlarged kidneys which appear echogenic, with multiple discrete cysts within them in high resolution suggestive of poly cystic kidneys (Fig. 3,4) and ultrasound of liver and biliary tree revealed multiple blind ending round and elongated cystic lesions without internal vascularity not communicating with the biliary tree likely biliary cysts (Fig. 5,6).

The echocardiography showed AV canal defect with Left to Right shunt (Fig. 7). She was started on antibiotics (renal dose), restricted fluids, oxygen, lasix and antihypertensive drugs and Nephrology consult was

taken. She was planned for renal biopsy and genetic study and further follow up once her condition improves. The parents were counselled for the same.

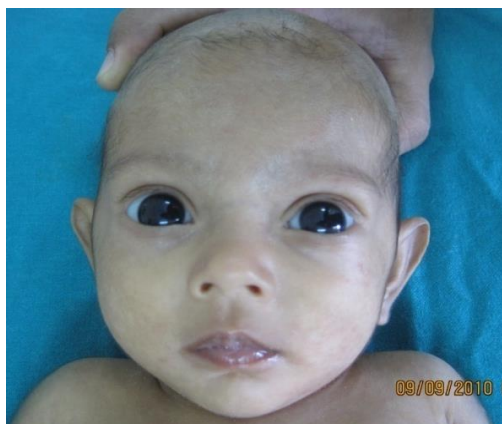

Fig. 1: Shows low set ears with long philtrum

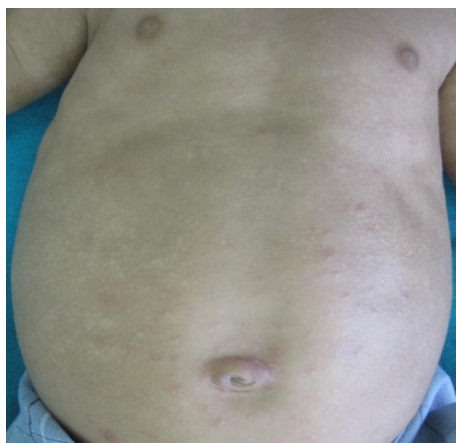

Fig. 2: Shows bilateral abdominal distension in flanks

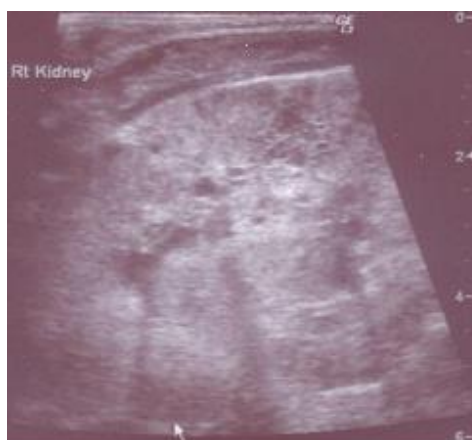

Fig. 3

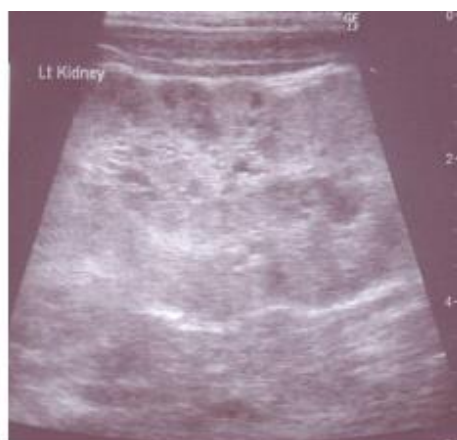

Fig. 4

Fig. 3 & 4: Shows bilateral enlarged kidneys which appear echogenic, with multiple discrete cysts within them in high resolution suggestive of poly cystic kidneys

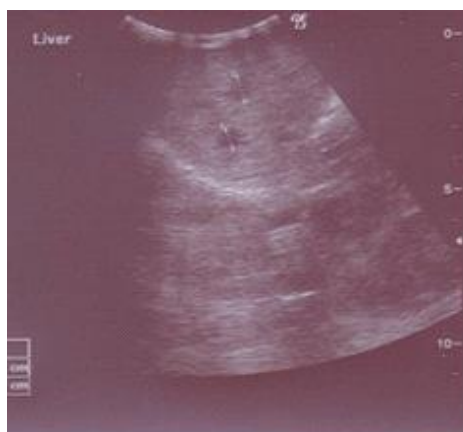

Fig. 5

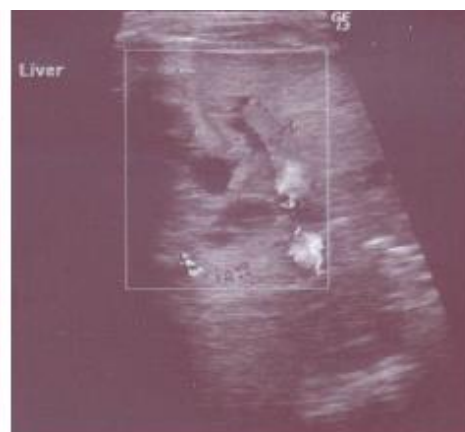


Fig. 6

Fig. 5 & 6: Shows multiple blind ending round and elongated cystic lesions without internal vascularity not communicating with the biliary tree likely biliary cysts

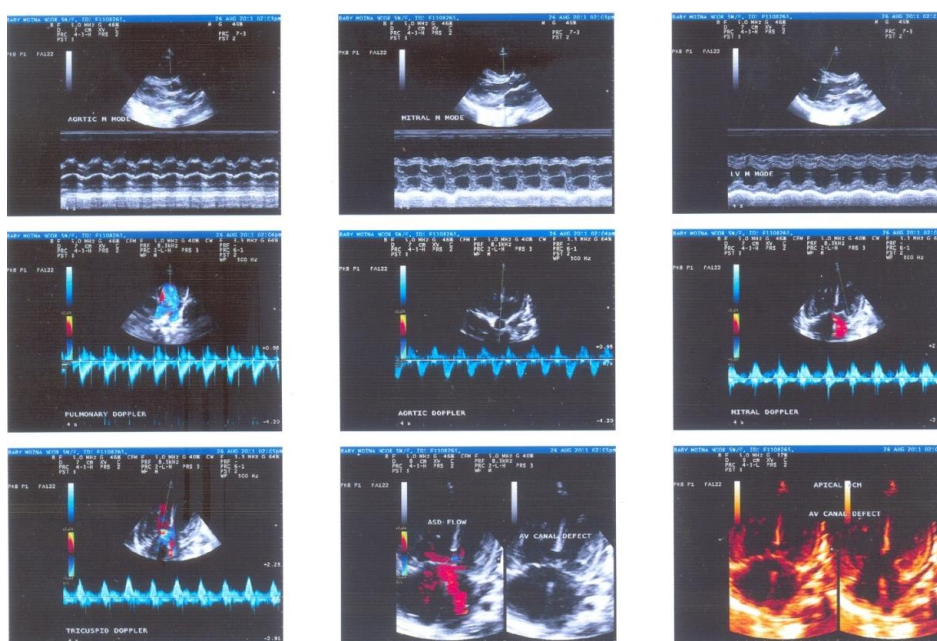


Fig. 7: Echocardiography showing AV canal defect with Left to Right shunt

Discussion

ARPKD, a heritable condition, is characterized by cystic dilations of the renal collecting tubules. It is the most common childhood-onset ciliopathy. The majority of patients present in infancy, although presentation can occasionally be as late as early adulthood. Extrarenal manifestations of this disorder include congenital hepatic fibrosis or Caroli disease, which involves non-obstructive dilation of intrahepatic bile ducts. The gene responsible for ARPKD is PKHD1 (located on chromosome 6), with most affected patients being compound heterozygotes. The patients are often diagnosed in utero with suggestive findings of enlarged kidneys, oligohydramnios, and absence of urine in the bladder. Clinically infants may have Potter's facies and large palpable flank masses with impaired renal function. Other presenting features may include

pulmonary insufficiency, transient hyponatremia, metabolic acidosis, and hypertension. Renal ultrasound is the usual imaging modality for confirmatory diagnosis.

The ultrasound characteristically demonstrates bilaterally enlarged, echogenic kidneys with poor corticomedullary differentiation (5, 6). Imaging of the liver generally demonstrates hepatomegaly with increased echogenicity and difficulty visualizing the periportal veins, as well as findings consistent with portal hypertension. Renal biopsy is generally not required, especially in patients who fulfill the diagnostic criteria for ARPKD or who have positive genetic testing. Liver biopsy may be helpful. Survival of neonates has improved with medical technological advances with an estimated 70% survival in affected infants in the first year of life. Management involves

correction of electrolyte abnormalities, respiratory support, nutritional support, and treatment of hypertension (7, 8). Dialysis in combination with unilateral or bilateral nephrectomy may be required to allow for optimal ventilation of the infant. Urinary abnormalities may be seen including concentrating defects, hematuria, proteinuria, and pyuria. Complications of ARPKD often relate to the hepatic system, including hepatomegaly, esophageal varices, portal vein thrombosis, portal hypertension, hypersplenism, and bacterial cholangitis. In our case there was no antenatal scan done as she was unbooked case. The female infant presented at 3 months of age with features of ARPKD with left to right shunt and features of Congestive cardiac failure. This rare association of ARPKD with AV canal defect is never been reported in the literature.

Conflict of Interest: None

Source of Support: Nil

References

1. Sweeney WE Jr, Avner ED. Molecular and cellular pathophysiology of autosomal recessive polycystic kidney disease (ARPKD). *Cell Tissue Res.* 2006 Dec. 326(3):671-85.
2. Zerres K, Mücher G, Bachner L, et al. Mapping of the gene for autosomal recessive polycystic kidney disease (ARPKD) to chromosome 6p21-cen. *Nat Genet.* 1994 Jul. 7(3):429-32.
3. Sharp AM, Messiaen LM, Page G, et al. Comprehensive genomic analysis of PKHD1 mutations in ARPKD cohorts. *J Med Genet.* 2005 Apr.42(4):336-49.
4. Gunay-Aygun M, Avner ED, Bacallao RL, et al. Autosomal recessive polycystic kidney disease and congenital hepatic fibrosis: summary statement of a first National Institutes of Health/Office of Rare Diseases conference. *J Pediatr.* 2006 Aug. 149(2):159-64.
5. O'Brien K, Font-Montgomery E, Lukose L, et al. Congenital hepatic fibrosis and portal hypertension in autosomal dominant polycystic kidney disease. *J Pediatr Gastroenterol Nutr.* 2012 Jan. 54(1):83-9.
6. Gunay-Aygun M, Font-Montgomery E, Lukose L, Tuchman Gerstein M, Piwnicka-Worms K, Choyke P, et al. Characteristics of congenital hepatic fibrosis in a large cohort of patients with autosomal recessive polycystic kidney disease. *Gastroenterology.* 2013 Jan. 144(1):112-121.e2.
7. Bajwa ZH, Sial KA, Malik AB, Steinman TI. Pain patterns in patients with polycystic kidney disease. *Kidney Int.* 2004 Oct. 66(4):1561-9.
8. Chapman AB. Approaches to testing new treatments in autosomal dominant polycystic kidney disease: insights from the CRISP and HALT-PKD studies. *Clin J Am Soc Nephrol.* 2008 Jul. 3(4):1197-204.