

Content available at: <https://www.ipinnovative.com/open-access-journals>

IP International Journal of Medical Paediatrics and Oncology

Journal homepage: <https://www.ijmpo.com/>

Case Report

Familial Hemophagocytic Lymphohistiocytosis (Type 2) with solitary neurological presentation due to PRF1 gene mutation

Saiprasad Onkareshwar Kavthekar¹, Namburu Sravanthi^{1,*}, Priti Bhimrao Kamble¹, Anil Bapurao Kurane¹, Rupali Naidu¹, Vilas Maruti Jadhav²

¹Dept. of Paediatrics, D.Y. Patil Medical College, D Y Patil Education Society (Deemed to be University), Kolhapur, Maharashtra, India

²Arya Children's Neurology Super Speciality Clinic, Kolhapur, Maharashtra, India



ARTICLE INFO

Article history:

Received 23-07-2022

Accepted 19-09-2022

Available online 27-10-2022

Keywords:

Children

Familial Hemophagocytic

lymphohistiocytosis

Neurological presentation

ABSTRACT

Familial hemophagocytic lymphohistiocytosis (FHLH) clinically manifest with fever, hepatosplenomegaly, pancytopenia, hyperferritinemia, hypofibrinogenemia and/or neurological signs. We report a case of solitary neurological presentation and absence of systemic signs of inflammation which was initially thought to be genetic leukodystrophy but latter turn out to be FHLH type 2 due to mutation in PRF1 gene. Pediatricians should keep FHLH as a differential diagnosis in a patient with solitary neurological presentation due to neuroinflammation even if no signs of systemic inflammation or abnormal laboratory parameters.

This is an Open Access (OA) journal, and articles are distributed under the terms of the [Creative Commons Attribution-NonCommercial-ShareAlike 4.0 License](https://creativecommons.org/licenses/by-nc-sa/4.0/), which allows others to remix, tweak, and build upon the work non-commercially, as long as appropriate credit is given and the new creations are licensed under the identical terms.

For reprints contact: reprint@ipinnovative.com

1. Introduction

Familial hemophagocytic lymphohistiocytosis (FHLH) is a systemic inflammation which presents by cytokine storm, multiorgan failure and high morbidity and mortality.¹ FHLH clinically manifest with fever, hepatosplenomegaly, hepatitis, pancytopenia, hyperferritinemia, hypertriglyceridemia, hypofibrinogenemia and/or neurological signs.² FHLH type 2 due to PRF 1 gene mutation can manifest during infancy or early childhood with solitary central nervous system (CNS) involvement due to neuroinflammation. CNS manifestations can be present initially or anytime during the course of disease.³

There were limited studies regarding solitary neurological presentation and FHLH. Here, we report a case of solitary neurological presentation due to

neuroinflammation along with absence of systemic signs of inflammation and also lacked abnormal laboratory parameters for FHLH and which was initially thought be genetic leukodystrophy but latter turn out to be FHLH type 2 due to mutation in PRF1 gene.

2. Case Report

Three years boy born out of consanguineous marriage was apparently well till five months of age and then he presented with two episodes of febrile seizures two months apart. He also had motor milestones regression with progressive spasticity and language delay. The boy was admitted in our hospital for status epilepticus and managed with antiseizure drugs, ventilator care and supportive management. He responded well to treatment and was off ventilator within two days and was put on maintenance antiseizure drugs. His cerebrospinal fluid (CSF) examination and fundus examination were normal.

* Corresponding author.

E-mail address: sravanthinamburu95@gmail.com (N. Sravanthi).

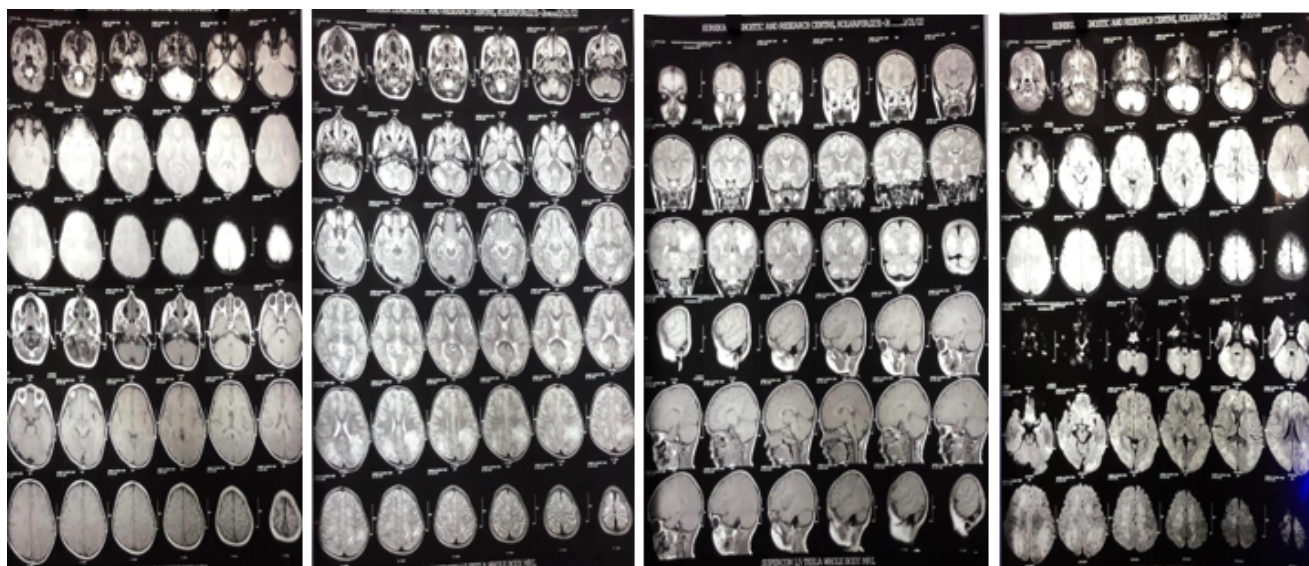


Fig. 1: MRI Images of patient suggestive of genetic leukodystrophy.

CLINICAL DIAGNOSIS / SYMPTOMS / HISTORY						
Baby Shrivardhan Bhikaji Sutaar, presented with clinical indications of progressive spasticity, motor regression and hyperreflexia. There is history of febrile seizures in early childhood. His brain MRI showed symmetric deep periventricular and posterior predominant white matter and T2/FLAIR hyperintensities with DWI restriction. He is suspected to be affected with adrenoleukodystrophy or leukodystrophy or metachromatic leukodystrophy and has been evaluated for pathogenic variations.						
RESULTS						
PATHOGENIC VARIANT CAUSATIVE OF THE REPORTED PHENOTYPE WAS DETECTED						
Gene* (Transcript)	Location	Variant	Zygosity	Disease (OMIM)	Inheritance	Classification
PRF1 (-) (ENST00000441259.2)	Exon 2	c.148G>A (p.Val150Met)	Homozygous	Familial hemophagocytic lymphohistiocytosis-2	Autosomal recessive	Pathogenic

Fig. 2: Whole exome sequencing report suggestive of FHLH due to PRF1 gene mutation.

His clinical examination showed spasticity in all limbs (Lower limbs>upper limbs), exaggerated deep tendon reflexes, plantars upgoing and ankle contractures with scissoring posture. There were no hepatosplenomegaly and other systemic examination was normal. The laboratory parameters showed complete blood count (Hb 11gm, WBC 9200/cu.mm, Neutrophils 70% platelets 255000cu.mm), CRP 6 mg/l, ESR 12mm/hr and serum Ferritin 175 ng/ml. The liver function test and metabolic workup was normal. MRI Brain showed large areas signal abnormality in both cerebral hemispheres, predominantly involving white matter including the centra semiovale, parieto-occipital and frontal lobe. These areas appear hypointense and hyperintense on T1 and T2 weighted images respectively along with patchy areas of restriction diffusion on Flair images. (Figure 1) These findings suggested the possibility of being secondary to an inherited metabolic disorder with dysmyelination such as adreno-leukodystrophy or metachromatic leukodystrophy. MRI spine was normal. In

view of clinical presentation and MRI picture a possible diagnosis of genetic leukodystrophy was kept and genetic study, whole exome sequencing was ordered. To our surprise, it reported FHLH type 2, homozygous variant with gene PRF1 and not any genetic leukodystrophy. (Figure 2) He was started with intrathecal methotrexate 10mg once 12 for weeks and injection hydrocortisone along with oral antiseizure drugs in maintenance doses and advised for hematopoietic stem cell transplantation (HSCT).

3. Discussion

FHLH is an autosomal recessive condition and known pathological gene mutations along with associated sub types include PRF1 (FHLH2), UNC12D (FHLH3), STX11 (FHLH4) and STXBP2 (FHLH5).⁴ These mutations can affect Natural Killer cells and T lymphocytes to synthesize and release perforin (Protein product of PRF1) and granzymes. This results in dysregulation in immune

system.³

Our patient presented with solitary neurological presentation without any systemic signs of inflammation and also lacked laboratory parameters of inflammation but still genetic studies showed PRF1 gene mutation (FHLH type 2). Although neurological presentations are common at FHLH diagnosis, these rarely precede systemic manifestations. Feng Wei-Xing et al³ reported four patients of FHLH in Chinese children who had only CNS presentation initially (seizures, coma, cranial palsies, ataxia, spasticity and gait abnormalities) and also missed the diagnosis as they thought of demyelinating condition like acute disseminated encephalomyelitis or multiple sclerosis. Aytac S et al⁵ studied 73 patients FHLH and observed ten (25%) patients with isolated CNS involvement without any infectious trigger. These patients presented with unexplained neurological presentation and cranial nerve palsies leading to misdiagnosis and mistreatment. Yang et al⁶ also found neurological symptoms in 13% children including seizures, coma, ataxia, hemiplegia and cranial nerve palsies. Similarly, in our patient also we misdiagnosed for leukodystrophy as our patient presented with spasticity mainly in lower limbs, gait abnormalities, motor regression and hyperreflexia along with seizures and also MRI picture is suggestive of genetic leukodystrophy.

Benson LA et al⁷ also reported four patients with isolated neuroinflammation associated with FHLH and concluded that precise diagnosis and HSCT can decrease morbidity in CNS FHLH. Henter et al¹ suggested that FHLH diagnosis should not be made by only acquired hemophagocytic lymphohistiocytosis diagnostic criteria. Studies done by Horne et al⁸ and Dias et al⁹ found neurological presentation in 20-73% of FHLH patients and observed that the systemic presentation may present late as disease is still evolving.

CSF neopterin level is a useful biomarker for CNS FHLH disease activity among broad group of neuroinflammatory disorders.¹⁰ But in our patient we could not able to do CSF neopterin level.

Our case report highlights that solitary CNS presentation due to neuroinflammation even in the absence of systemic inflammatory signs or normal laboratory parameters still can be FHLH.

4. Conclusion

Pediatricians should keep FHLH as a differential diagnosis in a patient with solitary neurological presentation due to neuroinflammation even if no signs of systemic inflammation or abnormal laboratory parameters. The genetic studies like whole exome sequencing should be ordered promptly for accurate diagnosis of FHLH.

5. Source of Funding

None.

6. Conflict of Interest

None.

References

- Henter JI, Horne A, Arico M, Egeler RM, Filipovich AH. diagnostic and therapeutic guidelines for hemophagocytic lymphohistiocytosis. *Pediatric Blood.* 2004;48(2):124–31. doi:10.1002/pbc.21039.
- Osinka I, Popko K, Demkow U. Perforin: an important player in immune response. *Central-Eur J Immunol.* 2014;39(1):109–15. doi:10.5114/cej.2014.42135.
- Feng W, Yang X, Li J, Gong S, Wu Y, Zhang W, et al. Neurological manifestations as initial clinical presentation of familial hemophagocytic lymphohistiocytosis type 2 due to PRE 1 mutation in Chinese pediatric patients. *Front Genet.* 2020;11:126. doi:10.3389/fgene.2020.00126.
- Dufourcq-Lagelouse R, Jabado N, Deist FL, Stéphan JL, Souillet G, Bruin M, et al. Linkage of Familial hemophagocytic lymphohistiocytosis to 10q21-22 and evidence of heterogeneity. *Am J Hum Genet.* 1999;64(1):172–9. doi:10.1086/302194.
- Aytac S, Balta G, Kuskonmaz B, Aksu T, Okur FV. Isolated CNS hemophagocytic lymphohistiocytosis in children: What we know, what we don't know. *Blood.* 2021;138(1):4190. doi:10.1182/blood-2021-153509.
- Yang S, Zhang L, Jia C, Ma H, Henter J. Frequency and development of CNS involvement in Chinese children with hemophagocytic lymphohistiocytosis. *Pediatric Blood Cancer.* 2010;54(3):408–15. doi:10.1002/pbc.22239.
- Benson LA, Li H, Henderson LA, Solomon IH, Soldatos A, Murphy J, et al. Pediatric CNS-isolated hemophagocytic lymphohistiocytosis. *Neurol Neuroimmunol Neuroinflamm.* 2019;6(3):e560. doi:10.1212/NXI.0000000000000560.
- Horne A, Trottestam H, Arico M, Egeler RM, Filipovich AH. Frequency and spectrum of central nervous system involvement in 193 children with hemophagocytic lymphohistiocytosis. *Br J Haematol.* 2008;140(3):327–35.
- Dias C, Macdonald A, Sincan M, Rupps R, Markello T. Recurrent subacute post viral onset of ataxia associated with PRF 1 mutation. *Eur J Hum Genet.* 2013;21(11):1232–9.
- Howells DW, Strobel S, Smith I, Levinsky RJ, Hyland K. Central nervous system involvement in the erythrophagocytic disorders of infancy: the role of cerebrospinal fluid neopterin in the differential diagnosis and clinical management. *Pediatric Res.* 1990;28(2):116–9. doi:10.1203/00006450-199008000-00008.

Author biography

Saiprasad Onkareshwar Kavthekar, Associate Professor

Namburu Sravanthi, Junior Resident

Priti Bhimrao Kamble, Assistant Professor

Anil Bapurao Kurane, Professor and HOD

Rupali Naidu, Junior Resident

Vilas Maruti Jadhav, Consultant Pediatric Neurologist

Cite this article: Kavthekar SO, Sravanthi N, Kamble PB, Kurane AB, Naidu R, Jadhav VM. Familial Hemophagocytic Lymphohistiocytosis (Type 2) with solitary neurological presentation due to PRF1 gene mutation. *IP Int J Med Paediatr Oncol* 2022;8(3):132-134.