



## Case Report

# Mesenteric and retroperitoneal chylus cyst in a neonate: unusual case report

Aravindh Radhakrishnan<sup>1</sup>, Sujoy Neogi<sup>1,\*</sup>, Shasanka Shekhar Panda<sup>1</sup>, Simmi K Ratan<sup>1</sup>, Anju Verma<sup>1</sup>

<sup>1</sup>Dept. of Pediatric Surgery, Maulana Azad Medical College(MAMC), New Delhi, India



### ARTICLE INFO

#### Article history:

Received 06-04-2020

Accepted 06-05-2020

Available online 18-07-2020

#### Keywords:

Mesenteric cyst

Chylous cyst

Chyle

Chylo-lymphatic cyst

### ABSTRACT

We are reporting an unusual case of diffuse chylous mesenteric cyst extending to the retroperitoneum in a neonate. The lump was unresectable as it was diffuse and mesenteric vessels traversed through it. The child was followed till one year of age and is asymptomatic. Repeat imaging shows persistence of the cysts.

© 2020 Published by Innovative Publication. This is an open access article under the CC BY-NC license (<https://creativecommons.org/licenses/by-nc/4.0/>)

## 1. Introduction

Intra-abdominal cysts can be mesenteric cysts and cystic lymphangiomas. There are distinguishable differences between the two entities.<sup>1</sup> Abdominal cystic lymphangiomas (ACLs) are rare congenital benign malformations of the lymphatic system that are usually located in the small-bowel mesentery, followed by the omentum, mesocolon and retroperitoneum.<sup>1</sup> Most lymphangiomas are found in the head and neck; intraabdominal locations are very unusual.

## 2. Case Report

A 25-day-old boy was brought to the emergency with a history of progressive abdominal distension since birth, associated with occasional non-bilious vomiting. There was no history of fever, bowel or bladder complaints. The birth history was uneventful, and the antenatal sonography did not show any intra-abdominal pathology. The child was hemodynamically stable. Abdomen was distended with a lump involving left lumbar, left hypochondrium, umbilical, hypogastrium and left iliac fossa. The lump was not moving

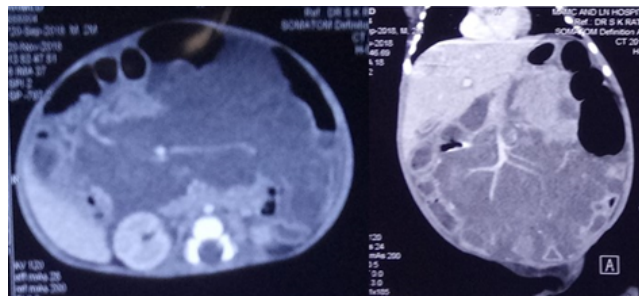
with respiration and percussion over the lump revealed a dull note. Ultrasound and CT scan (Figure 1) reported a provisional diagnosis of mesenteric lymphangioma with mesenteric vessels traversing through it.

Laparotomy was done in view of the tense distension and was approached by right supra-umbilical transverse incision. The mesentery corresponding to ileum and jejunum was studded with multiple cysts of various sizes containing white milk like fluid (Figure 2). In addition, there was large solid lump at the base of the mesentery which was fixed to the retroperitoneum. An incision biopsy from both mesenteric and retroperitoneal mass was sent for frozen section which was reported as benign lympho-vascular lesion. In view of the diffuse nature of the cysts and the mesenteric vessels traversing through the second lump at the base of the mesentery, a decision for intra-operative injection Bleomycin was taken, as the recommended treatment of complete resection seemed rather too radical for this child. De-roofing of some large cysts was also done to relieve the distension. Final histopathology report showed endothelial lining with smooth muscles consistent with lymphangioma and the biochemical assessment was consistent with chyle. Post-

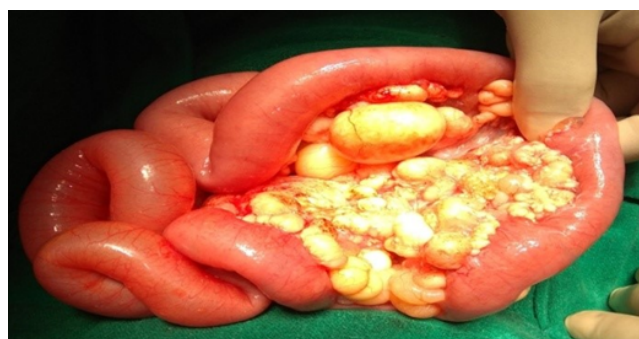\* Corresponding author.

E-mail address: [drsujoneogi@yahoo.com](mailto:drsujoneogi@yahoo.com) (S. Neogi).

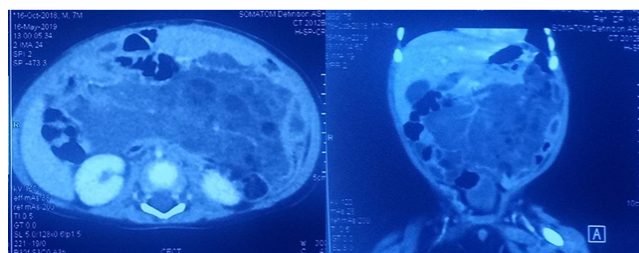
operative period was uneventful. Child accepted oral feeds and passed regular stools. The child was closely followed up every monthly for increase in distension and development of signs of intestinal obstruction. No further intra-lesional Bleomycin was possible, which was part of the original plan, due to unavailability of safe window. However, at one year follow up the child is asymptomatic without any further distension. There was no episode of bowel obstruction. Repeat sonography and CECT abdomen was done which still revealed a multi-cystic lesion in the mesentery (Figure 3).



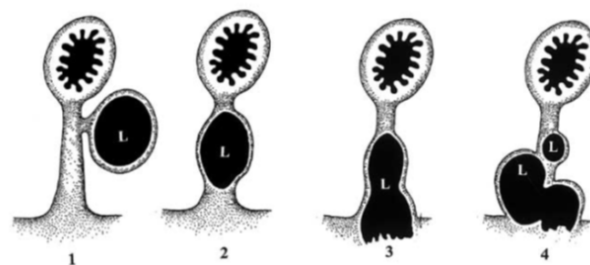
**Fig. 1:** CECT transverse and coronal section showing the mass displacing the bowel and the mesenteric vessels traversing through it.



**Fig. 2:** Showing mesentery studded with multiple chylous cysts



**Fig. 3:** Showing transverse and coronal cuts of the lump after one year follow up without much change in the size.



**Fig. 4:** Shows the classification of ACL proposed by Losanoff et al

### 3. Discussion

Mesenteric cysts and cystic lymphangiomas are infrequently encountered intra-abdominal lesions that may be confused by their gross appearance but are distinguishable by their histologic and ultrastructural characteristics. The study by Takiff et al has shown that lymphangiomas are large, symptomatic, and rare lesions usually found in children particularly in male babies. Besides being large, they are also multiloculated and associated with ascites. In contrast mesenteric cysts are uncommon but not rare lesions seen commonly in female adults. They are generally small, unilocular, asymptomatic and occasionally calcified lesions. The locations of these lesions also vary, with lymphangiomas more often being diffuse within the abdomen and mesenteric cysts often located entirely within the omentum. Lymphangiomas may, therefore, require resection of adjacent organs to achieve complete resection. Cystic intra-abdominal lesions have been categorized by the nature of the fluid they contain. The fluid may be serous, chylous, bloody or purulent. The presence of chyle depends more on the location than on the histology of the lesion. The presence of chyle in nonlymphatic cyst is due to proximity to intestinal lacteals and possibly to fatty degeneration.<sup>1</sup>

According to Losanoff et al cystic lymphangiomas involving the mesentery are rare, fewer than 200 detailed reports published in the English literature. The specific number of mesenteric cystic lymphangiomas (MCL) is uncertain because most reports provide incomplete histologic differentiation MCL and other mesenteric cysts. MCLs occur at all ages, though most (65%) are present at birth, and 90% become symptomatic before second year of life. MCLs usually contain serous, serosanguinous or chylous fluid. The treatment of MCL is surgical. Although the lesions have a generally benign course, they tend to recur and invade neighboring structures. Total removal of a lesion that invades potentially resectable intra-abdominal structures such as bowel, spleen or pancreas is possible, but adhesion to vital structures makes resection impossible thus necessitating other measures like partial resection, marsupialization, and sclerotherapy. The latter is associated with high degree of recurrence. This study proposed a new classification system for MCL (Figure 4).<sup>2</sup>

1. Type 1 is a pedicled MCL whose complete resection is possible
2. Type 2 is a sessile MCL located in mesenteric boundaries. Sometimes bowel needs to be resected along with the cyst.
3. Type 3 is a MCL with retroperitoneal extension. Involvement of vital structures makes complete resection impossible.
4. Type 4 describes multicentric MCLs. The involvement is too extensive.

Neonatal chylous cysts of mesentery, without involvement of retroperitoneum, has been reported in the literature. However, the biopsy report either did not match the clinical finding<sup>3,4</sup> or biochemically not consistent with chyle.<sup>4,5</sup>

Gallart et al also corroborated that Abdominal cystic lymphangiomas (ACL) are exceedingly rare. The majority are detected in infants and children less than 5 years of age. There are few reports of prenatal diagnosis of this condition cited in the available literature. Histopathologically they are characterized by a thin wall cover by endothelium positive for CD31 and containing smooth muscle, adipose cells, and lymphatic tissue. Diffuse chronic inflammatory infiltration composed by lymphocytic aggregates is usually seen below the endothelial lining. ACL usually contains chylous milky fluid because of the protein and fat content, corresponding with our case. ACL have a varied clinical spectrum, depending on its size and location. Most ACL in adults presented with vague and obscure abdominal non-specific symptoms while in children prominent abdomen and pain with or without vomiting is usually noticed. The vast majority of children with ACL present with abdominal distention with or without palpable mass. Cystic mass may be difficult to palpate in routinely physical examination because its fluid consistence and freely great mobility. Various complications have been associated with ACL. These include intestinal obstruction, intestinal gangrene due to volvulus, cystic intracavitary hemorrhage, infection, traumatic rupture and torsion of the cyst. No malignant conditions have been noticed in pediatric patients. Nearly 50% of ACL present with some grade of ascites. Differential diagnosis in childhood must include other fluid-filled benign abdominal lesions as intestinal duplication cyst, ovarian cyst, choledochal cyst, cystic teratomas and dermoids, hydronephrosis, pancreatic or splenic cyst, hydatid cyst and ascites. The paper also talks about the various investigations used to differentiate ACL from the other differentials. Plain abdominal X-ray has no diagnostic value for detecting ACL but could be useful for detecting bowel obstruction. Abdominal ultrasound is the first-line diagnostic procedure in cases of suspected ACL. Ultrasonography usually shows a fluid-filled cystic lesion with well-circumscribed thin walls often containing septa. Abdominal CT scan could demonstrate the origin of the cystic lesion, anatomical relationships and mass size. Wall of the lesion usually shows a strong enhancement after contrast injection. MRI

is probably the most useful diagnostic procedure to assess mass relationships with neighbouring structures but cannot differentiate between dermoid cyst, cystic teratoma, cystic lymphangioma or lymphocele. MRI can demonstrate low signal intensity in T1-weighted and high signal intensity in T2-weighted images. ACL may show high signal intensities in both T1 and T2-weighted images due to infection, volvulus or haemorrhage. A preoperative diagnosis is better accomplished combining both CT scan and MRI.<sup>6</sup>

The treatment of ACL and mesenteric cyst is clearly surgical and complete excision has been advocated in the literature.<sup>7-9</sup> Some authors have reported difficulty in resecting retroperitoneal ACL and had attempted partial resection which has led to recurrences in some cases.<sup>9</sup> One report of conservative management of ACL with favorable results has also been published.<sup>10</sup>

#### 4. Conclusion

Our case is an unusual case of abdominal cystic lymphangioma diffusely involving mesentery and retroperitoneum. We believe the chyle in the mesenteric component is due to the proximity to the bowel. We could not find a similar case in a newborn with such extensive involvement and unresectability. It was also interesting to note that the child continues to be asymptomatic even after a long follow up.

#### 5. Source of Funding

None.

#### 6. Conflict of Interest

None.

#### References

1. Takiff H, Calabria R, Yin L, Stabile B. Mesenteric cysts and intra-abdominal cystic lymphangiomas. *Ann Surg.* 1985;120(11):1266–9.
2. Losanoff J, Kjossev KT. Mesenteric cystic lymphangioma: unusual cause of intra-abdominal catastrophe in an adult. *Int J Clin Pract.* 2005;59(8):968–7.
3. Gupta AR, Nanavati RN, Fernandez A, Kalgutkar A, Nathani R, Deshmukh S, et al. Chylous mesenteric cyst: an unusual cause of neonatal intestinal obstruction. *Indian Pediatr.* 1992;29:511–3.
4. Karaca I, Hosgor M, Sencan A, Etensel B, Mir E. Abdominal cystic lymphangioma: A rare cause of acute abdomen in a neonate. *Pediatr Int.* 2001;43:525–6.
5. Panjwani K, Gangopadhyay A, Sharma S, Gupta D, Chooramani G, et al. Ideal treatment strategy for chylous mesenteric cyst: a case report. *Indian J Pediatr.* 1993;60:712–4.
6. Méndez-Gallart R, Bautista A, Estévez E, Rodríguez-Barca P. Abdominal Cystic Lymphangiomas in Pediatrics: Surgical Approach and Outcomes. *Acta Chir Belg.* 2011;111(6):374–377.
7. Steyaert H, Guitard J, Moscovici J, Juricic M, Vaysse P, Juskiewenski S, et al. Abdominal cystic lymphangioma in children: benign lesions that can have a proliferative course. *J Pediatr Surg.* 1996;31(5):677–80.
8. Konen O, Rathaus V, Dlugy E, Freud E, Kessler A, Shapiro M, et al. Childhood abdominal cystic lymphangioma. *Pediatr Radiol.* 2002;32:88–94.

9. Hebra A, Brown M, McGeehin K, Ross A. Mesenteric, omental, and retroperitoneal cysts in children: a clinical study of 22 cases. *South Med J.* 1993;86(2):173–6.
10. Amodeo I, Cavallaro G, Raffaelli G, Colombo L, Fumagalli M, Cavalli R, et al. Abdominal cystic lymphangioma in a term newborn. *Med.* 2017;96:e5984.

**Shasanka Shekhar Panda** Associate Professor

**Simmi K Ratan** Professor

**Anju Verma** Senior Resident

### Author biography

**Aravindh Radhakrishnan** Senior Resident

**Sujoy Neogi** Associate Professor

**Cite this article:** Radhakrishnan A, Neogi S, Panda SS, Ratan SK, Verma A. **Mesenteric and retroperitoneal chylus cyst in a neonate: unusual case report.** *IP Int J Med Paediatr Oncol* 2020;6(2):75-78.